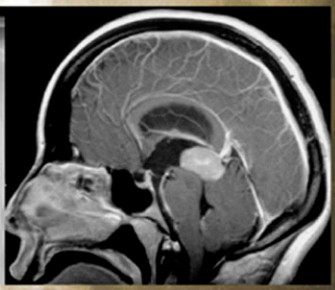

RAPID REVIEW OF

Radiology

SHAHID HUSSAIN
SHERIF A. A. LATIF
ADRIAN D. HALL

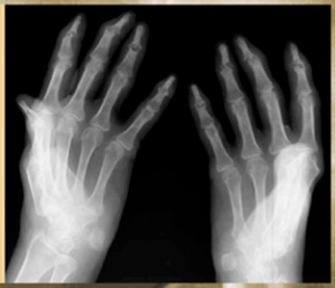

MANSON PUBLISHING

Rapid Review of

Radiology

Shahid Hussain
MA, MB, BChir, MRCP, FRCR
Consultant Radiologist
Heart of England NHS Foundation Trust, Birmingham, UK

Sherif Aaron Abdel Latif
MB, ChB, MRCS, FRCR
Consultant Radiologist
Dudley Group of Hospitals NHS Foundation Trust, West Midlands, UK

Adrian David Hall
MB, ChB, MRCP, FRCR
Consultant Radiologist
Dudley Group of Hospitals NHS Foundation Trust, West Midlands, UK

MANSON
PUBLISHING

Dedications

S.H. – To my mum

S.L. – To my mum and dad, my wife Darine and baby Danny

A.H. - For my parents, my wife Kirstie and my sons Oliver, Tristan and Seb

Copyright © 2010 Manson Publishing Ltd

ISBN: 978-1-84076-120-7

All rights reserved. No part of this publication may be reproduced, stored in a retrieval system or transmitted in any form or by any means without the written permission of the copyright holder or in accordance with the provisions of the Copyright Act 1956 (as amended), or under the terms of any licence permitting limited copying issued by the Copyright Licensing Agency, 33–34 Alfred Place, London WC1E 7DP, UK.

Any person who does any unauthorized act in relation to this publication may be liable to criminal prosecution and civil claims for damages.

A CIP catalogue record for this book is available from the British Library.

For full details of all Manson Publishing Ltd titles please write to:
Manson Publishing Ltd, 73 Corringham Road, London NW11 7DL, UK.
Tel: +44(0)20 8905 5150
Fax: +44(0)20 8201 9233
Website: www.mansonpublishing.com

Commissioning editor: Jill Northcott
Project manager: Jane Fricker
Design: Cathy Martin, Presspack Computing Ltd
Colour reproduction: Tenon & Polert Colour Scanning Ltd, Hong Kong
Printed by: Replika Press Pvt Ltd, Kundli, Haryana, India

Contents

Preface 4

Contributors 5

Abbreviations 5

General Introduction 7

Chapter 1 – Chest Imaging 11

Chapter 2 – Abdominal Imaging 71

Chapter 3 – Central Nervous System, Head and Neck Imaging 147

Chapter 4 – Musculoskeletal Imaging 205

Chapter 5 – Paediatric Imaging 289

Chapter 6 – Breast Imaging *by Professor Iain Lyburn* 331

Further Reading 343

Index of Differential Diagnoses 344

General Index 346

Preface

As in all specialties, learning in radiology is a lifelong process. Yet the rate of learning is undoubtedly highest in the trainee years, when there is a vast amount of information to assimilate. There are many excellent, comprehensive radiology texts available to facilitate this, yet learning for most of us is a more haphazard process than reading such a text from cover to cover. More commonly, we learn initially unrelated pieces of information from multiple sources and these gradually join together like the pieces of a jigsaw, using the comprehensive textbook as a reference along the way. The practical aspects of image recognition and formulating a differential diagnosis become ever more important, especially as postgraduate exams loom! Again, there are already excellent radiology atlases and text-based differential diagnosis guides that become standard reading for the trainee.

Our aim in writing this text was to bring together the images with the differential diagnosis information, adding some practical advice along with it. Such a book cannot be comprehensive without becoming another large general text. Instead, we have tried to compile a selection of cases covering many aspects of radiology, particularly the types used in radiology vivas. These include the so-called 'Aunt Minnie' cases, where a classic image becomes simple pattern recognition, and also the cases where findings need to be pieced together along with the clinical history to formulate a differential diagnosis. This selection of cases will thus provide image and factual learning material for a broad sample of disorders that will intertwine with material learnt elsewhere. The format is intended to help the trainee starting out with practical issues such as how to approach films and the vocabulary to use; the trainee approaching exams with a means of self-testing and rehearsing cases; and also the nonradiologist to practise some more challenging material. The selection of cases is hopefully broad enough to provide an introduction to some 'exam favourites' for the beginner, but also more testing cases for those in later stages of training.

In order for the candidate to test him- or herself, we have presented each case as an image (or set of images) together with the pertinent clinical details. Over the page is a description of the images as would be given to an examiner in a long case or a viva situation. This is perhaps the most important part in getting to the correct diagnosis since the description contains the relevant positive and negative imaging findings, and will help to identify the correct diagnosis as well as narrow down the differentials. The correct diagnosis for the film is given, followed, in most cases, by a differential diagnosis list, which contains the best diagnoses to fit with the images and history. A discussion of the underlying diagnosis is then presented; this includes teaching points and main imaging findings regarding the diagnosis and any other important conditions that emerge in the course of the discussion. Each case concludes with practical tips and notes on further management.

We have tried to include as many plain radiograph images as possible, since these still constitute the primary investigation performed in radiology departments. Subsequent investigation is usually based on these initial images and therefore their correct interpretation cannot be understated. In the abdominal chapter, we have also included many barium contrast images, which are often poorly performed on in examinations. Subsequent multimodality images have been included – ultrasound, CT, MRI, interventional radiology and nuclear medicine. In this way, we have presented the imaging cases as they would appear in both exam situations and in the real world. For example, chest disease would be initially investigated with a chest x-ray, with subsequent investigation with a CT. CNS disease is usually initially investigated with CT/MRI. We have therefore tried to follow the clinical investigation pathway as closely as possible to present trainees with the images in the order in which they would expect to see them, in exams and clinical situations.

The lists of differential diagnoses, radiological signs and practical tips are often presented in 'bullet point' list format to allow for rapid revision just before the exams. We have also indexed the differential diagnosis lists allowing for easy and quick referral throughout training, and when it comes time to revise. Hopefully, we have provided a book that can be referred to throughout the radiologist's training, through various levels of ability.

Shahid Hussain, Sherif Latif and Adrian Hall

Contributors

Professor Iain Lyburn, Consultant Radiologist, Gloucestershire Hospital NHS Foundation Trust for the breast imaging chapter.

Dr Bernd Wittkop, Consultant Radiologist, Worcestershire Acute Hospitals Trust for the nuclear medicine cases.

For the contribution of images: Dr Anne Gregan, Consultant Radiologist, Dudley Group of Hospitals NHS Trust; Dr Peter Oliver, Consultant Radiologist, Dudley Group of Hospitals NHS Trust; Dr Ruth Shave, Consultant Radiologist, Dudley Group of Hospitals NHS Trust; Dr Katharine Foster, Consultant Radiologist, Birmingham Children's Hospital NHS Foundation Trust; Dr Umesh Udeshi, Consultant Radiologist, Worcestershire Acute Hospitals Trust; Dr Dee Dawkins, Consultant Radiologist, Sandwell & West Birmingham Hospitals NHS Trust; Dr Hong Gap-Teo, Consultant Radiologist, Sandwell & West Birmingham Hospitals NHS Trust; Dr Colin Walker, Consultant Radiologist, University Hospital Birmingham NHS Foundation Trust; Dr J Reynolds, Consultant Radiologist, Heart of England NHS Foundation Trust; Dr M Djearaman, Consultant Radiologist, Heart of England NHS Foundation Trust; Dr A Pallan, Consultant Radiologist, Heart of England NHS Foundation Trust; Dr S Roy-Choudhury, Consultant Radiologist, Heart of England NHS Foundation Trust; Dr S Cooper, Consultant Radiologist, Heart of England NHS Foundation Trust.

We would especially like to thank Dr L Arkell for the film library she collated over the course of her career and passed on at retirement, many cases from which have been used in the course of this text.

Abbreviations

ABC	aneurysmal bone cyst
ABPA	allergic bronchopulmonary aspergillosis
AD	autosomal dominant
ADC	apparent diffusion coefficient
ADEM	acute disseminated encephalomyelitis
ADPKD	autosomal dominant polycystic kidney disease
AF	atrial fibrillation
AIDS	acquired immunodeficiency syndrome
ANA	antinuclear antibodies
AP	anteroposterior
ASD	atrial septal defect
AVM	arteriovenous malformation
AVN	avascular necrosis
AXR	abdominal x-ray
BP	blood pressure
CAD	computer-aided detection
CAM	cystic adenomatoid malformation
CC	craniocaudal
CDH	congenital diaphragmatic hernia
CF	cystic fibrosis
CFA	cryptogenic fibrosing alveolitis
CMV	cytomegalovirus
CNS	central nervous system
COP	cryptogenic organizing pneumonia
CP	cerebellopontine
CRM	circumferential resection margin
CSF	cerebrospinal fluid
CT	computed tomography
CVA	cerebrovascular accident
CWP	coal worker's pneumoconiosis
CXR	chest x-ray
DCIS	ductal carcinoma *in situ*
DWI	diffusion weighted imaging
EAA	extrinsic allergic alveolitis
ECG	electrocardiogram
ECMO	extracorporeal membrane oxygenation
ENT	ear, nose and throat
ERCP	endoscopic retrograde cholangiopancreatography
FAP	familial adenomatous polyposis
FDG	18 fluoro-2-deoxyglucose
FFDM	full-field digital mammography
FLAIR	fluid attenuated inversion recovery
FNA	fine needle aspiration
FNH	focal nodular hyperplasia
GBM	glioblastoma multiforme
GCT	giant cell tumour
Gd-BOPTA	gadolinium benzyloxypropionic-tetra-acetate
Gd-EOB-DTPA	gadolinium-ethoxybenzyl-diethylenetriamine penta-acetic acid

GI	gastrointestinal
HIV	human immunodeficiency virus
HMD	hyaline membrane disease
HPOA	hypertrophic pulmonary osteoarthropathy
HRCT	high-resolution computed tomography
HRT	hormone replacement therapy
HSP	Henoch–Schönlein purpura
HSV	herpes simplex virus
HU	Hounsfield units
IAC	internal auditory canal
IDC	invasive ductal carcinoma
ILC	invasive lobular carcinoma
IPF	idiopathic pulmonary fibrosis
ITU	intensive treatment unit
IV	intravenous
IVC	inferior vena cava
IVU	intravenous urogram
LP	lumbar puncture
MCA	middle cerebral artery
MCUG	micturating cystourethrogram
MEN	multiple endocrine neoplasia
MIBG	meta-iodobenzylguanidine
MIP	maximum intensity projection
MISME syndrome	multiple inherited schwannoma, meningioma and ependymoma
MLO	mediolateral oblique
MRA	magnetic resonance angiography
MRCP	magnetic resonance cholangiopancreatography
MRI	magnetic resonance imaging
MS	multiple sclerosis
MSK	musculoskeletal
NAI	non accidental injury
NEC	necrotizing enterocolitis
NF1	neurofibromatosis type 1
NG	nasogastric
NOS	not otherwise specified
NSAIDs	nonsteroidal anti-inflammatory drugs
OA	osteoarthritis
OKC	odontogenic keratocyst
OPG	orthopantomogram
PA	posteroanterior
PCA	posterior cerebral artery
PCP	*Pneumocystis carinii* pneumonia
PD	proton density
PDA	patent ductus arteriosus
PET	positron emission tomography
PICA	posterior inferior cerebellar artery
PIE	pulmonary interstitial emphysema
PMF	progressive massive fibrosis
PNET	primitive neuroectodermal tumour
PSC	primary sclerosing cholangitis
PVL	periventricular leukomalacia
RA	rheumatoid arthritis
RTA	renal tubular acidosis
SACE	serum angiotensin converting enzyme
SAH	subarachnoid haemorrhage
SBC	simple bone cyst
SI	superioinferior
SLE	systemic lupus erythematosus
SMV	superior mesenteric vein
STIR	short tau inversion recovery
SUFE	slipped upper femoral epiphysis
SVC	superior vena cava
TB	tuberculosis
TCC	transitional cell carcinoma
TE	time to echo
TIA	transient ischaemic attack
TIPS	transjugular intrahepatic portosystemic shunt
TME	total mesorectal excision
TNM	tumour–node–metastases staging
TOF	tracheoesophageal fistula
UBOs	unidentified bright objects
UC	ulcerative colitis
US	ultrasound
UTI	urinary tract infection
VAD	vacuum assisted device
VATS	video assisted thorascopic surgery
VHL	von Hippel–Lindau syndrome
VSD	ventricular septal defect

GENERAL INTRODUCTION

This book has been written primarily for senior radiology trainees preparing for final radiology exams and in particular for trainees studying for the Fellowship of the Royal College of Radiology. With this in mind, the cases presented herewith have been presented in the exact manner that the cases are presented in the Royal College of Radiology FRCR 2B exam. In the exam, long cases and viva cases are presented with a very minimal but highly relevant history and the required response is expected to be presented in a particular way. This format of reporting[1] involves giving a Description/Interpretation of the images; Diagnosis; Differential Diagnosis; and advice on Further Management. We have laid out the answers here in exactly this manner and have included a Discussion to give in-depth further information about each condition which will enable the student to answer any questions directed to him or her in the viva situation. By following the RCR exam format, the candidate should be ideally prepared for this exam and for the future as a Consultant Radiologist.

FILM TECHNIQUE

Whatever the imaging modality, the radiologist interprets images using all the information and clues available, to produce a differential diagnosis and/or advise on further investigation and management. Above all else, this must be done in a SAFE manner, and this often requires one to be systematic in approach. Secondly, this process must be done in a SENSIBLE manner – it is easy to quote endless lists of differential diagnoses but if these are not refined for each individual case, the radiologist's input is of little value. The following discussion concentrates in particular on performing these tasks in the examination viva scenario. However, much of the advice is applicable to everyday practice too, in particular the emphasis on a safe and sensible approach.

TYPES OF FILM

The types of film one may encounter in an exam/viva are as follows:

The 'Aunt Minnie'

There are certain disorders that have a characteristic appearance on imaging that allows one to make an instant 'spot diagnosis'. It will be assumed the candidate has come across it before, and thus the best preparation here is exposure to as many of these cases as possible. Radiological atlases and film libraries provide ready access to many of these classic cases, which can then be committed to memory. You can prepare a ready-made description of these cases for the viva. If you are sure of the diagnosis, dispatch the film promptly with your preprepared 'speech' so that you can progress to the next case as soon as possible. Of course there may be 'Aunt Minnie' cases that you haven't seen and this may present a problem. Such cases are often not amenable to working out the diagnosis – you either know it or you don't. The only thing to do is be methodical in your analysis and description of the findings so that at the very least you can suggest whether you feel an abnormality is likely to be longstanding and benign or otherwise, and make appropriate suggestions on how you would proceed.

The 'test of observation'

Here, there is an abnormality present that once seen, may well lead to an easy diagnosis. The abnormality is subtle or hidden however, such that it tests the candidate's perception and approach to a case. Perceptual ability, however, is variable, not only between people but also in the same observer on different days (this is particularly true in examinations where anxiety levels are high). You must therefore be systematic in analysing each film if there is no obvious abnormality to see on first inspection. There are many different systematic approaches and it is beyond the scope of this discussion to be more prescriptive. However, make sure you have a system and use it. Moreover, describe the process you are going through aloud in the viva so that the examiner knows that you are practising safe radiology.

The 'jigsaw puzzle'

This type of case presents several findings that once identified and considered together, lead to a specific or differential diagnosis. This not only tests perceptual skill and systematic approach, but also the ability to mentally 'cross-reference' several differential diagnosis lists for the various abnormalities identified, to find the 'best fit' diagnosis. Whenever producing a differential diagnosis in an examination or real life, it is vital to produce a sensible list, not just a recital of long lists learnt from books. To do this, you must use all clues available from the clinical history and film, and combine this information with knowledge of the incidence of each possibility in a given patient population.

The 'discussion'

In the real world, there are many abnormal radiological studies that have no specific 'best fit' diagnosis, but rather a differential diagnosis that cannot be narrowed down without further investigation. It is easy to assume that all cases used to test an examination candidate will have a single correct answer but this is a dangerous assumption – these 'real world' cases with no specific diagnosis are clearly a good test of how a radiologist will operate in daily practice. As always, a safe and systematic approach to film analysis is vital, together with a sensible approach to a differential diagnosis. Such cases, in particular, also assess the other role of the radiologist – advising on further investigation and management.

ANALYSING THE CASE

As already emphasized, have a system of analysis for all types of film. More specific advice on possible approaches will be given in further chapter introductions.

Use all clues available to you. Background clinical information is most important when interpreting radiological studies, so listen very carefully to any information the examiner provides with the case. Make a note of the age and sex of the patient if possible using either identification data on the film or anatomical information – many disorders can be eliminated or suspected from the differential diagnosis list on the basis of such simple information. Specific features on the film may also help narrow down the differential diagnosis – the presence of central venous cannulae and airway intubation immediately indicates a seriously ill patient for example.

Examiners will often try to help you. For example, they may offer further information, affirm your suggestions or perhaps suggest you might like to reconsider something you have said. It is fairly safe to assume they are not trying to mislead you deliberately, so do not ignore their hints. If their hints lead you to reconsider previous statements as erroneous, do so graciously and honestly – you cannot fool them that you knew all along.

PRESENTING THE CASE

When presenting any radiological film in an exam or as a report in clinical practice, the approach should be the same. The Royal College of Radiology has given guidance on the required format that reports in the long cases/viva should take and this is as we have presented the cases in this book. After briefly looking at the film, present the:

Description

Relevant positive and negative radiological findings in a systematic manner, summarizing the findings at the end of the description.

Diagnosis

Try to identify relevant information in the history/patient data/radiological findings/other investigations which narrows the differential list down.

Differential diagnosis

Give a list of differentials for the findings.

Further management

Suggest further investigations to confirm the diagnosis or suggest further clinical management.

Obviously, the description is presented dynamically at the same time as evaluating the film and this requires some mental 'multitasking'. You can afford a brief pause when the case is presented to make an initial assessment, but after a few seconds, further silence does not create a good impression. Introductory statements such as 'This frontal chest radiograph of an adult male…' or 'this AP radiograph of the humerus in an unfused skeleton…' are not only appropriate, but also buy you another brief moment to think. In the initial stages of assessing an abnormality prior to reaching a conclusion, be careful not to use specific terminology that implies a specific diagnosis.

Even when you are completely unsure of what the abnormality is, it is still important to keep talking thus providing evidence that you continue to approach a film systematically and safely, even when you are uncertain. Summarizing your negative findings can often be as important as the positive ones and even if you remain oblivious to any abnormality after considered review of the case, verbally excluding acute life-threatening possibilities in your analysis shows, at the very least, a degree of safety in your practice.

Asking questions of the examiner to help interpret the film is usually acceptable, but only after you have made a considered assessment of the film and have either offered some thoughts or made it clear that you are merely seeking final confirmation of a particular possibility you have in mind. Asking questions early on, before you have made a systematic analysis of the case, however, only points to desperation.

The final stage of suggesting further investigation or management is vital in illustrating that you are a safe and valuable practitioner. If you have identified a life-threatening emergency on a film, statements such as 'I would contact the referring doctor immediately' are essential. Finally, when considering whether further investigation should be suggested, you may well note that the examiner already has a film ready to show you.

It is useful to practise ways of ending a case because there is danger in continuing to talk and talk about a case when you have already reached the limit of what you can interpret from it – it is all too easy to 'dig yourself into a hole' in this situation, making comments that appear indecisive. If you have already suggested a differential diagnosis, likely diagnosis and suggested further management options, you have naturally provided a conclusion – just make sure you look at the examiner when doing so to clearly make the point that you have finished.

If you are uncertain about what the film shows, it can be more difficult. However, if you have reached an impasse and cannot proceed any further, options available include presenting a summary of your observations, suggesting further investigations, asking for more information, etc. (always looking at the examiner).

GENERAL VIVA CONSIDERATIONS

- **Practice makes perfect.**
  Practice sessions in groups where you get to watch your colleagues being tested are particularly useful as you can learn much from their errors and successes. As well as honing your radiological skills, take note of irritating personal habits that might be better resolved before your real examination (e.g. fidgeting). Practise your descriptive findings for the classic exam-type cases so that you can dispatch these cases quickly and with confidence.

- **See as much material as possible.**
  Time spent looking through film libraries and radiological atlases will build up a knowledge base of classic exam-type cases, whilst time spent looking at endless 'everyday' studies not only fosters sensible 'real world' practice, but will also turn up pathology and build up your mental database of 'normal appearances'.

- **Don't give up.**
  Anxiety levels are high during examinations and can lead to foolish errors. However, never assume that a particular case has gone so badly that overall failure is inevitable. There are no doubt many candidates who have failed an exam, not because of the single case they thought they had failed, but because of the cases they failed thereafter because of this presumption and altered mental state. Every case is a new opportunity to demonstrate your ability, irrespective of how badly the previous case went.

- **Be thorough.**
  At the same time, however, it is advantageous to get through as many cases as you can. Thus, when you are presented with an 'Aunt Minnie' case of which you are confident, proceed quickly and confidently through it using your preprepared 'speech'.

- **Do not miss life-threatening or serious conditions.**
  Make sure you check for conditions such as a fracture and pneumothorax when you have failed to identify any other abnormality.

- **Be safe.**
  Most of all, show that you are safe and sensible in your practice.

Reference

1. Royal College of Radiology Guidance on Format of Reporting Session Reports for FRCR Part 2B; http://www.rcr.ac.uk/content.aspx?PageID=713

SUMMARY

Use the same structured format for reporting radiology cases, which consists of:

DESCRIPTION

Give your OBSERVATIONS on the films including relevant positive and negative findings and then give your INTERPRETATION of these findings.

DIAGNOSIS

Give the 'best fit' diagnosis for the image findings.

DIFFERENTIAL DIAGNOSIS

Give a limited number of possible differential diagnoses for the image findings.

FURTHER MANAGEMENT

Give suggestions for relevant further investigations and immediate management which need to be undertaken.

This page intentionally left blank

Chapter 1

CHEST IMAGING

The approach to plain chest radiographs and to chest CT scans is essentially the same and it requires a systematic approach to the images presented. A suggested approach to these images is presented here, though it is worth finding a systematic approach that works best for you, covering all of the important areas and that you find easy to remember. Ensure that whichever approach you take, it is well practised and well rehearsed, since it becomes rapidly obvious to examiners whether or not you have looked at and regularly reported this type of film before. As always, you should be able to modify the specific order in which you carry out your systematic analysis depending on the most apparent findings.

THE PLAIN CHEST RADIOGRAPH

Initial assessment

There are three vitally important things to do when first presented with a chest radiograph:

1. Make a quick mental note of any technical inadequacies that might influence further interpretation, e.g. suboptimal exposure, rotation. Remember that in an exam situation the examiner will have brought their best example of a given case, so although it is worth noting the flaws in the film, vocalizing these would not be advised unless they are significantly hampering your ability to make a diagnosis.

2. 'Unforgivable misses': there are a few conditions that you must simply never miss:
- Pneumothorax – in particular tension pneumothorax is a medical emergency requiring an immediate chest drain.
- Free gas under the diaphragm, indicating perforation of an abdominal viscus.

In real life the clinical history will often guide you to these, but in a viva, it is worth making a rapid exclusion of such conditions early on in your own mind before you become immersed in detailed evaluation and discussion of the case. Missing such serious abnormalities is unacceptable and only spotting them after several minutes of evaluation doesn't inspire confidence!

3. In a viva, you have about 10–15 seconds to make your initial evaluation before you need to start speaking – any information that can be gained about the patient's sex, age and ethnicity will be useful in making a diagnosis, so look for this information on the film.

Lines

Comment on the additional lines that you can see on the film – these may include ECG leads, oxygen tubing, NG tube, central venous catheters, chest drain and pacemakers/wires. These are important, first because you should assess that they are in the correct place and that their insertion has had no complications, e.g. ensure the NG tube is in the stomach, that there is no pneumothorax associated with the jugular central line. Secondly, identifying lines is important in assessing how unwell the patient is – your differential diagnosis is clearly going to be different if the chest radiograph is from an intubated ITU patient than if it is from an outpatient.

Lungs

First assess the chest to ensure that the general opacification in both lungs is the same – if not, then you need to determine which is the abnormally hyper or hypo transradiant lung and determine what the cause is. Mastectomy is one obvious cause that must not be missed as a history of breast cancer means the film must be checked carefully for evidence of metastatic spread.

Once you have decided what/where the abnormality is then describe the findings using a common vocabulary that is understood by all and which leaves no room for confusion. Accordingly, abnormalities can be described as:
- Focal or diffuse.
- Located in upper/middle/lower zones (avoids the difficulty of assessing lobes at the outset).
- Central or peripheral.
- Single or multiple.
- Exhibiting calcification or cavitation.

Broadly speaking lung abnormalities consist of:

Focal pulmonary lesion

You need to assess whether there are single or multiple lesions. Is there calcification? Is there cavitation? The differential diagnosis will depend on these patterns and useful information that will help you to narrow down the diagnosis can be sought from the examiner, such as a history of pyrexia, weight loss, haemoptysis, etc.

Diffuse pulmonary opacity

First, make a distinction between alveolar (airspace) and interstitial opacity. The former has a poorly defined, fluffy, cottonwool-like appearance, while the latter consists of reticular opacities, nodular opacities or a combination of both. The differential diagnosis will often be very different, as explained in subsequent cases in this chapter.

Hila
Assess the hila for position (left should be slightly higher than the right), shape (a V-shape made by the angle of the superior pulmonary artery and inferior pulmonary vein) and size.
- A change in the position of the hilum suggests volume loss. Accompanying interstitial opacity suggests fibrosis, whereas airspace opacity might suggest atelectasis, for which there are many causes, in particular obstructing masses.
- If there is change in the hilar angle or size then this would suggest a hilar mass such as enlarged nodes or central tumour.

Mediastinum
Comment on the heart size – is it enlarged or small? If there is any doubt from observation alone, state that you would like to formally measure it. Assess the mediastinal contour, including the cardiac contour itself and the great vessels. Ensure the trachea is central, that there is no pneumomediastinum or pneumopericardium. Large mediastinal masses will be readily evident but check that there is no loss of the paratracheal stripe due to smaller masses such as lymphadenopathy.

Pleura
Pleural lesions form an obtuse angle with the chest wall, as compared to a lung parenchymal lesion, which forms an acute angle. A differential list for pleural lesions should be easily brought to mind. Check for underlying rib destruction as a sign of a malignant nature. Always consider a pleural origin for opacities projected over the lungs but with unusual appearance, e.g. the typical 'holly leaf' pattern of pleural plaques.

Bones
Check the ribs, looking for:
- Lytic/sclerotic lesions to suggest metastases.
- Fractures – if present look for a pneumothorax or other signs of trauma. Certain fractures, such as those of the upper three ribs, suggest significant trauma and a high index of suspicion for other injuries is required.
- Rib resection from a previous thoracotomy.

Check the thoracic spine, not forgetting to pay attention to the paravertebral soft tissues that may point to underlying bony abnormalities. The cervical spine may be partly seen – look for a cervical rib.

Bony abnormalities around the shoulders present some favourite cases for vivas, so don't forget to check these areas towards the edge of the film!

Review areas
Everyone will have particular areas on certain investigations that they forget to evaluate well. These areas vary for each individual, but there are certain recurring patterns of missed abnormalities on the chest radiograph. So know your own perceptual 'blind spots'. In general, it is useful to check:
- Behind the heart – to look for a hidden mass or left lower lobe collapse.
- At the lung apices – is there a Pancoast tumour there?
- Beneath the diaphragm – is there free gas/splenomegaly/liver lesion?
- At the edges of the film – for a bone abnormality.

General tips
- Comparison with previous films is very useful in everyday practice. A solitary pulmonary nodule measuring 2 cm but not present on a film taken just a few months ago may well be neoplastic, whereas a stable appearance over many years makes this unlikely.
- Once you have described the film and given a differential diagnosis, only then ask for other studies or more clinical information if it will help narrow down the list of possibilities or aid management – it shows that you are able to make a differential list with no clinical information and then narrow this down in line with the clinical scenario. This is radiology in practice!

CT THORAX
Just as for the plain radiograph, one must systematically evaluate lungs, mediastinum, pleura, bones, peripheral soft tissues, etc. In doing so, it is of course important to utilize soft tissue, bone and lung 'windows' if available. Make a note of whether IV contrast has been given.

Lungs
Focal lesions may well be obvious but don't forget to check for more subtle abnormalities. Look carefully for interstitial abnormalities, paying particular attention to any relation to the secondary pulmonary lobule. Is the overall lung density normal and homogeneous? Poor inspiration will cause an artefactual increase in lung attenuation but will be evident by inward bowing of the posterior wall of the trachea. Don't forget to check the airways both large and small. Modern multidetector CT scans provide excellent visualization of the pulmonary vasculature when IV contrast is given – check for emboli.

Mediastinum
Check for normal patency and anatomy of great vessels, excluding aneurysm, dissection flaps, etc. Assess for abnormal lymphadenopathy. Assess heart for size, morphology, normal myocardial enhancement, filling defects, etc. Modern CT scans often demonstrate the proximal coronary arteries even without specific cardiac gating techniques. Don't forget to follow the superior mediastinum into the lower neck and supraclavicular fossae.

Pleura
Small pleural nodules and plaques can be easily missed if not specifically evaluated. Pneumothorax may well only be evident on lung windows.

Bones
Bone windows are essential. Multiplanar reformats made possible by multidetector CT scanners make assessment of the spine and ribs much easier than axial images alone.

Soft tissues and the 'periphery'
Just as with the chest radiograph, check the soft tissues of the chest wall, breast, neck, axillae and the upper abdomen on the lowest scans for hidden or incidental pathology.

CASE 1

History

A 34-year-old Caucasian male presented to his GP with a dry cough and shortness of breath for 3 months. He was otherwise fit and well.

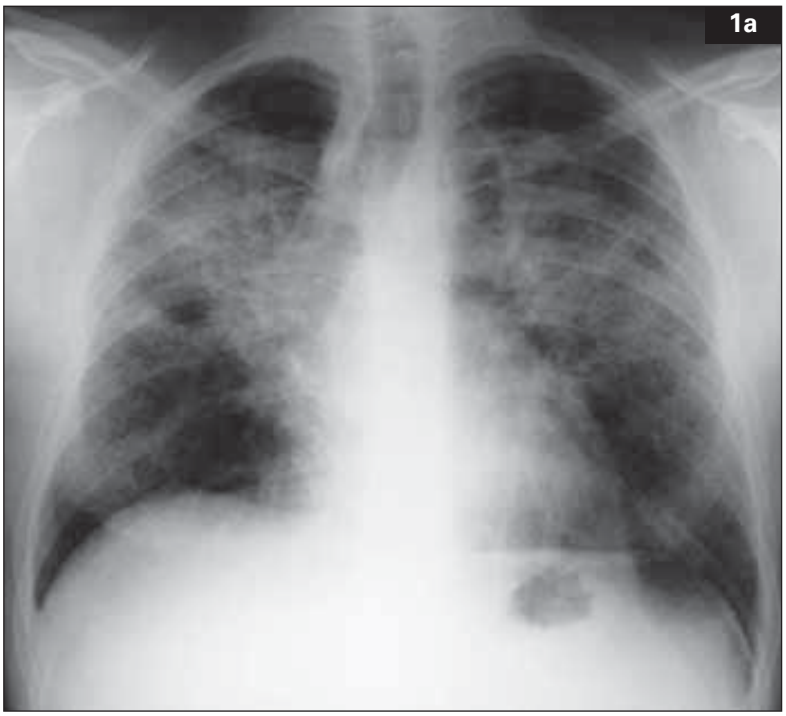
1a

CASE 2

History

A 32-year-old Asian male presented with productive cough, shortness of breath and night sweats.

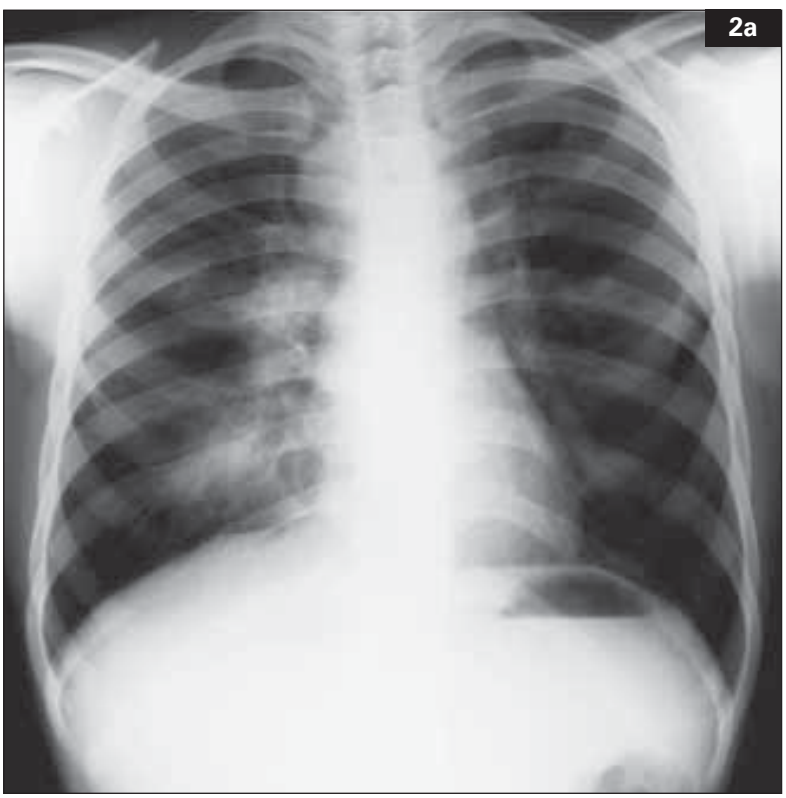
2a

ANSWER 1

Observations (1a)

This chest radiograph shows bilateral reticulonodular shadowing predominantly affecting the mid and upper zones with sparing of the absolute apices. The nodules are small, ~3–4 mm in diameter, and appear ill defined, and form confluent airspace opacities centrally. There is hilar enlargement more obvious on the right, and also widening of the right paratracheal soft tissues due to lymphadenopathy. Given the clinical details, sarcoidosis is the most likely diagnosis.

Diagnosis

Pulmonary sarcoidosis.

Differential diagnosis

For hilar node egg shell calcification:
- Sarcoid.
- Silicosis.
- Lymphoma following radiotherapy.

For bilateral hilar enlargement:
- Sarcoid.
- Lymphoma.
- TB.

For perilymphatic nodules:
- Sarcoid.
- Silicosis.
- Coal worker's pneumoconiosis (CWP).
- Lymphangitis carcinomatosa.
- Lymphoma.

Discussion

Sarcoidosis is a systemic disorder characterized by the presence of noncaseating granulomas within several organs. It most commonly presents in young adults in the 3rd–5th decades, and is more common in women and in black populations. Multisystem involvement can result in uveitis, bilateral parotid enlargement, erythema nodosum, lupus pernio, arthralgia, heart block, cardiomyopathy and bony changes most commonly seen in the phalanges.

Radiological features of pulmonary sarcoidosis are as follows:
- Lymphadenopathy (70–80%) is characterized by bilateral, symmetrical hilar lymph node enlargement and paratracheal lymphadenopathy. Egg shell calcification of the nodes (**1b**) is seen in ~5% of patients. Lymphadenopathy without pulmonary changes has a more favourable outcome. Figure **1c** shows bilateral hilar lymphadenopathy with no parenchymal disease.
- The most common form of parenchymal change is multiple small pulmonary nodules within the mid and upper zones of both lungs – the distribution described in this case is classical. Presentation with larger nodules measuring 1–5 cm, possibly with central cavitation and calcification, account for ~5% of cases. Airspace opacities are seen in 2–10%.
- End stage disease results in upper zone fibrosis with associated traction bronchiectasis.
- Chest radiograph changes have been classified from 0–4 as follows:
  Stage 0 – Normal film.
  Stage 1 – Lymphadenopathy only.
  Stage 2 – Lymphadenopathy and pulmonary infiltrate.
  Stage 3 – Pulmonary changes without adenopathy.
  Stage 4 – Pulmonary fibrosis.

Diagnosis is usually confirmed by HRCT of the thorax. The classical finding is of very small pulmonary nodules

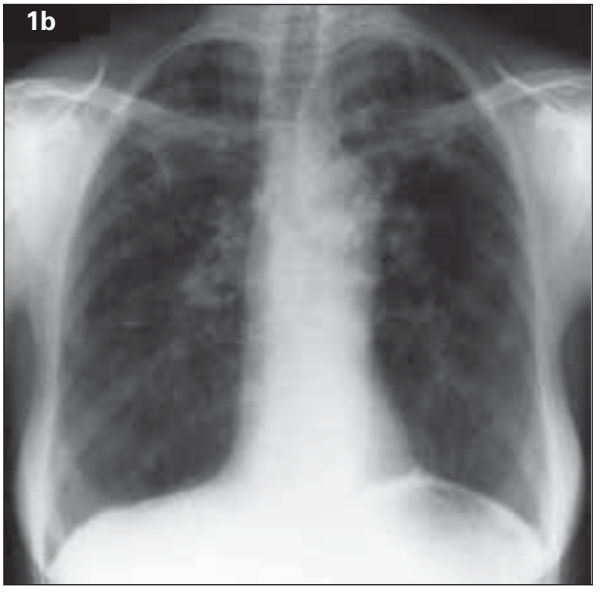

1b Chest radiograph shows bilateral hilar enlargement with hilar lymph node egg shell calcification.

1c Axial CT image shows bilateral hilar lymphadenopathy.

distributed in a perilymphatic manner, i.e. along the bronchovascular bundles, the interlobular septae and subpleural region (**1d**).

Practical tips

- Whenever there is evidence of adenopathy and abnormal pulmonary opacities, always consider sarcoidosis in the differential diagnosis.
- The features described above are largely the classical appearances. However, sarcoid can have almost any appearance on a chest radiograph, so be wary of categorically dismissing the diagnosis when the chest film shows abnormal pulmonary parenchyma. Conversely, it will often be a reasonable condition to list in the differential diagnoses because of its protean appearances.
- HRCT is very useful for further evaluation. Look for nodularity along the bronchovascular bundles, interlobular septae and pleura. Pleural nodularity due to subpleural lymphatic spread is often easiest to appreciate at the interlobar fissures where multiple layers of pleura make the changes more apparent.

Further management

- Gallium scanning is now rarely used in diagnosing the condition and in assessing disease activity. Recognized patterns of activity include the 'lamda' sign (paratracheal and bilateral hilar uptake) and the 'panda' sign (uptake in the parotid, salivary and lacrimal glands gives appearance of a panda face).
- Elevated serum angiotensin converting enzyme (SACE) levels may provide further supportive evidence of the diagnosis and the degree of disease activity.

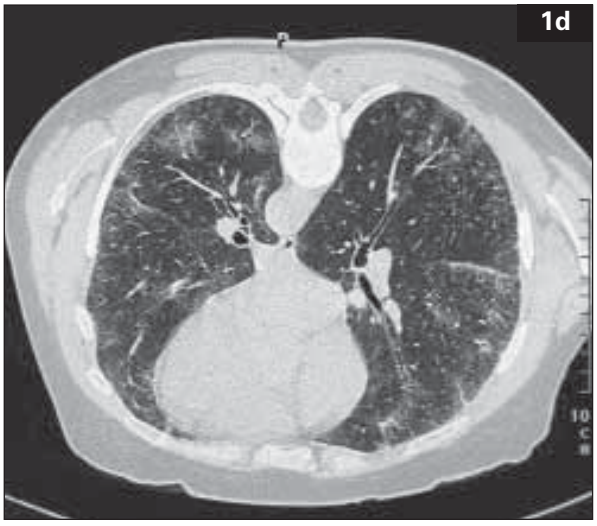

1d HRCT axial image demonstrates multiple nodules distributed along the bronchovascular bundles and subpleural regions with nodular thickening of the interlobular septum.

ANSWER 2

Observations (2a)

The chest radiograph shows consolidation in the medial segment of the right middle lobe. There are right hilar and right paratracheal nodular, soft tissue density opacities consistent with lymphadenopathy. No pleural effusions are seen.

Given the clinical details and radiological appearances, pulmonary TB is most likely.

Diagnosis

Primary tuberculosis (TB).

Differential diagnosis

For consolidation and lymphadenopathy:

- TB.
- Sarcoid.
- Lymphoma.
- Other infective organisms: histoplasmosis, mycoplasma, varicella.

Discussion

Although primary TB usually presents in children, there is now increasing incidence in adults. Primary TB now accounts for 23–34% of all adult cases of TB.

Unlike post-primary pulmonary TB that usually manifests in the upper lobes, primary TB affects lower lobes, middle lobes and anterior segment of the upper lobes. Presentation is with:

- Parenchymal airspace consolidation.
- Lymphadenopathy – the patterns of distribution are usually unilateral hilar +/– right paratracheal lymphadenopathy or isolated right paratracheal lymphadenopathy. Bilateral lymphadenopathy is unusual and when it does occur, is usually asymmetric.
- Miliary tuberculosis.
- Pleural effusion – seen in 23–38%.
- Tuberculoma.

(*cont.*)

Complications of TB include:

- Progressive primary TB – due to a failed immune response with subsequent disease progression.
- Miliary TB – massive haematogenous dissemination.
- Post-primary/reactive TB – presents in adults, with reactivation of dormant organisms after several asymptomatic years. Usually the apical and posterior segments of the upper lobes are involved (85–95%), the superior segment of the lower lobes being less commonly affected. Radiological presentation is with cavitation, fibrosis, empyema, miliary TB, tuberculoma, mycetoma. Adenopathy is not a major feature.

HRCT can be useful for further evaluation and TB presents with nodules in a centrilobular distribution due to endobronchial spread. This gives a 'tree in bud' appearance. The differential diagnosis for centrilobular nodules includes TB, endobronchial metastases, allergic bronchopulmonary aspergillosis (ABPA), obliterative bronchiolitis and hypersensitivity pneumonitis. Figures **2b** and **2c** show axial CT images demonstrating multiple poorly defined centrilobular nodules giving a 'tree in bud' appearance in a young male Asian patient with TB. Note that there is sparing of the subpleural areas with no nodules seen within 5 mm of the pleural surfaces or fissures.

Practical tips

TB is a multisystem disorder with haematogenous spread to multiple other sites. On a chest radiograph look for TB discitis and TB affecting shoulder joints. The most commonly affected joint is the hip with features of monoarticular involvement. Radiographic changes of loss of joint space, peripheral bone erosions and juxta-articular osteoporosis are seen, which can lead to ankylosis of the joint and limb shortening (**2d**).

Further management

Respiratory referral with a view to sputum cytology/bronchoscopy to identify the acid fast bacilli.

Further reading

Harisinghani MG, McLoud TC, Shepard JO, *et al.* (2000). Tuberculosis from head to toe. *Radio Graphics* **20:** 449–470.

Kim HY, Song KS, Goo JM, *et al.* (2001). Thoracic sequelae and complications of tuberculosis. *Radio Graphics* **21:** 839–858.

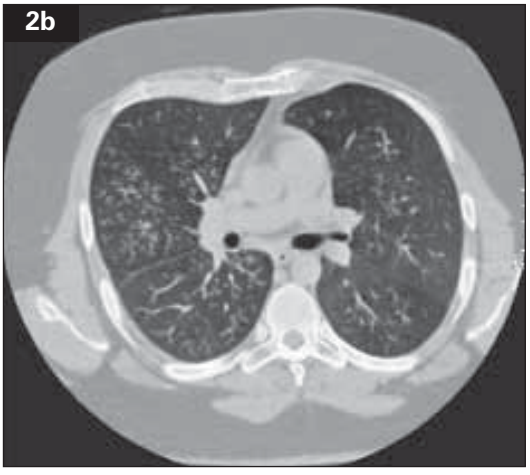

2b, 2c Axial CT images of the chest showing widespread centrilobular nodules giving a 'tree in bud' appearance.

2d There is marked erosion of the left femoral head with ankylosis of the hip joint. Marked limb shortening is the consequence.

CASE 3

History

A 65-year-old male presented with progressive dyspnoea and weight loss.

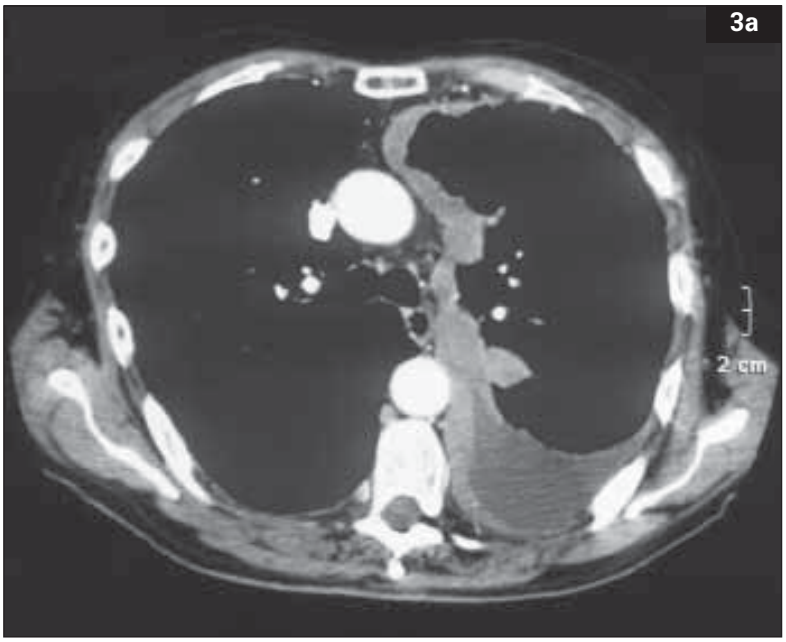

CASE 4

History

A 68-year-old male presented with haemoptysis.

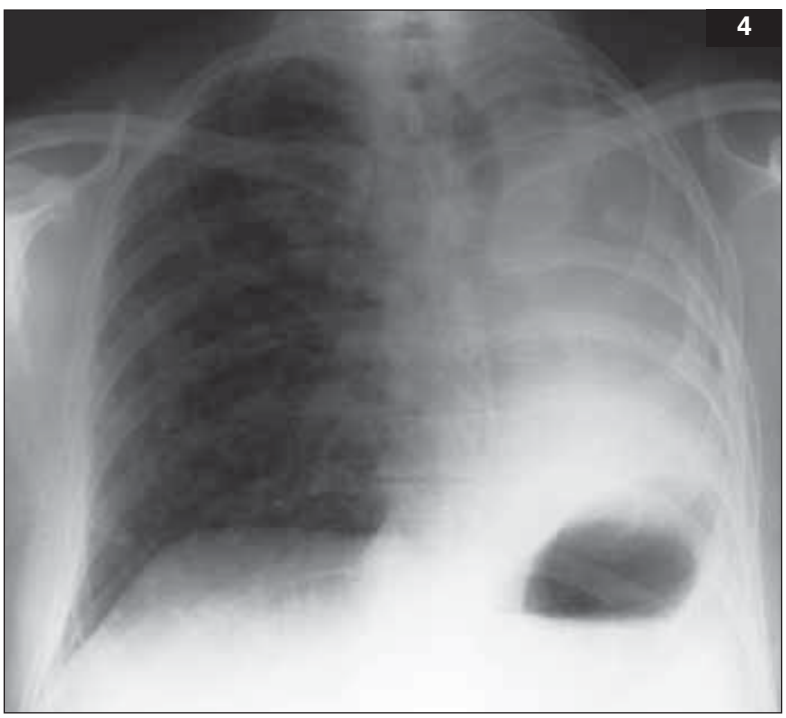

ANSWER 3

Observations (3a)

CT image of the thorax shows diffuse, irregular and nodular pleural thickening in the left hemithorax. This measures upwards of 1 cm in thickness and also involves mediastinal pleura. No focal intraparenchymal pulmonary abnormality is seen on these soft tissue window settings and there is no visible mediastinal mass. Taken together with the clinical history, the features are suspicious of mesothelioma, though metastases cannot be excluded. With regard to the former, the rest of the CT scan should be examined for features of asbestos-related pleural disease and asbestosis. An occupational history should also be taken.

Diagnosis

Malignant mesothelioma.

Differential diagnosis

For diffuse pleural thickening:

- Malignant mesothelioma.
- Pleural metastases – usually from adenocarcinoma primary, e.g. breast, lung.
- Empyema.
- Pleural fibrosis from infection – tuberculosis, fungal.

Discussion

Malignant mesothelioma is a rare primary tumour of the pleura, seen more commonly in men, with a peak incidence in the 7th–8th decades. Aetiology is strongly associated with asbestos exposure, and underlying lung changes from asbestos are often seen in association. Between 5 and 10% of asbestos workers will develop mesothelioma with a latent period of up to 45 years. The parietal pleura is usually involved and spread is locally to the chest wall, mediastinum, diaphragm and peritoneum; there is lymphatic spread to the hilar and mediastinal nodes and haematologically to lungs, liver and adrenals. Unilateral pleural effusion is commonly seen, but with no mediastinal shift due to the tumour creating a 'fixed' or 'frozen' hemithorax.

Prognosis is poor, with life expectancy of 12 months after diagnosis. Treatment including radiotherapy, chemotherapy and radical surgical pleurectomy produces universally poor results.

Practical tips

- Pleural thickening involving the mediastinal pleura is a very good sign for mesothelioma.
- Bilateral, calcified pleural plaques are characteristic of asbestos exposure. (Figure **3b** is a single axial CT image showing calcified pleural plaques, which are characteristic of asbestos exposure.) When identified, examine the CT closely for evidence of asbestosis as this may have greater immediate implications for the patient in terms of morbidity (and in the UK at least, financial compensation).

Further management

- Pleural biopsy is required to confirm the diagnosis and to differentiate mesothelioma from pleural metastatic disease, which can show some response to chemotherapy.
- Discussion within a lung cancer multidisciplinary team is required.
- A detailed occupational history needs to be taken since asbestos-related disease may entitle the sufferer to compensation.

Further reading

Wang ZJ, Reddy GP, Gotway MB, *et al.* (2004). Malignant pleural mesothelioma: evaluation with CT, MR imaging, and PET. *RadioGraphics* **24:** 105–119.

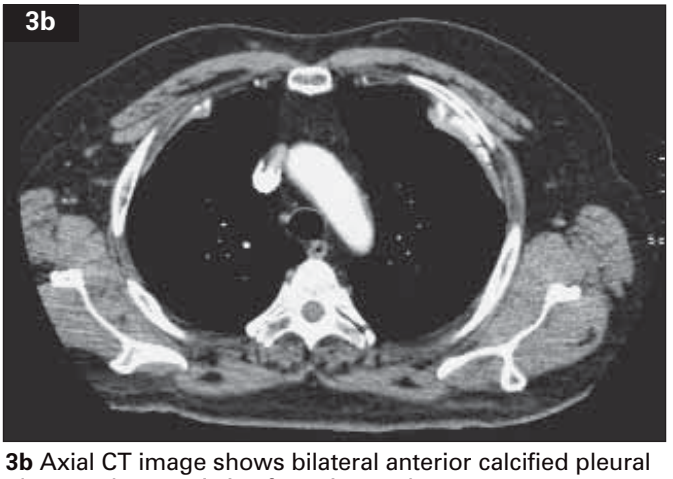

3b Axial CT image shows bilateral anterior calcified pleural plaques characteristic of previous asbestos exposure.

ANSWER 4

Observations (4)

This chest radiograph shows complete opacification of the left hemithorax with mediastinal shift to the left as evidenced by the displaced trachea and elevated left hemidiaphragm. There is a defect in the posterior aspect of the left 5th rib in keeping with a previous thoracotomy and presumed left pneumonectomy. In the right lung, there are multiple small miliary nodules seen throughout the lung. With evidence of previous pneumonectomy, these most likely represent miliary metastases from a previously resected bronchogenic tumour.

Diagnosis

Miliary metastases from previous bronchogenic carcinoma.

Differential diagnosis

For miliary nodules:

- Miliary metastases.
- TB.
- Sarcoid.
- Chronic extrinsic allergic alveolitis.
- Coal worker's pneumoconiosis (CWP).
- Histoplasmosis.

Of a completely opaque hemithorax:

- Total lung collapse.
- Pneumonectomy – looks like total collapse but there will be evidence of thoracotomy.
- Huge pleural effusion – volume expansion rather than volume loss, i.e. the mediastinum will be displaced away from the side of opacity.

Discussion

Thyroid cancer is classically described as a primary carcinoma likely to produce miliary metastases (others include melanoma and sarcoma). However, breast and lung cancer can less typically produce this pattern, but because they are more prevalent, may well be seen more often.

Practical tips

- This fairly straightforward case illustrates how films used to test candidates in postgraduate exams will often require 'piecing together of the pieces' rather than being presented with miliary shadowing alone and being asked for a differential.
- As always, look for other clues on the film. A primary malignancy may be evident as a mastectomy, a thyroid mass in the neck, a bony sarcoma on the edge of the film or signs of previous lung cancer, as in this case.
- Check the patient data for likely ethnicity to help predict likelihood of TB.

Further management

- Comparison with previous chest radiographs to look for new features is very useful and should be done in both clinical and exam situations.
- A chest CT will characterize these changes in greater detail.

CASE 5

History

A 40-year-old male presented with haemoptysis and renal impairment.

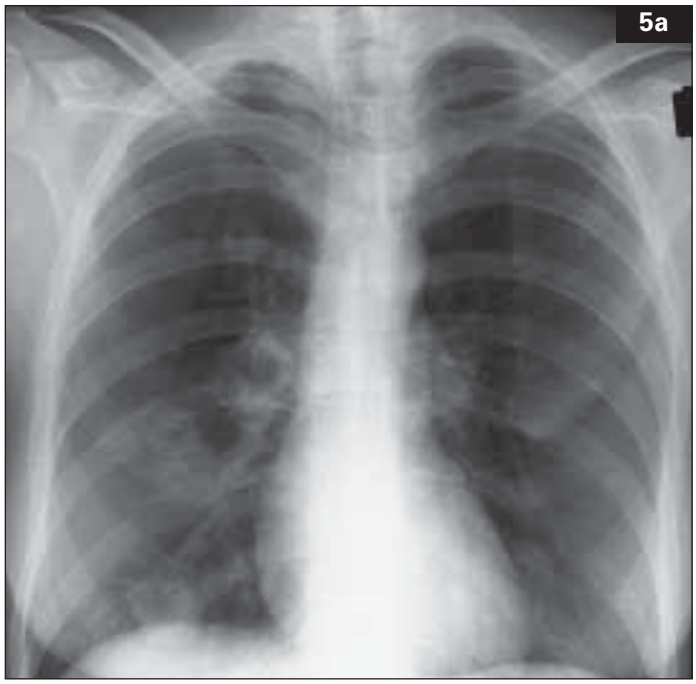

ANSWER 5

Observations (5a)

This frontal chest radiograph shows multiple relatively thick walled cavitating nodules throughout both lungs. Mediastinal contours are normal with no evidence on the film of hilar or mediastinal lymphadenopathy. No pleural effusion can be seen. Appearance of the shoulder joints and the lateral ends of the clavicles is normal.

Diagnosis

Wegener's granulomatosis.

Differential diagnosis

For multiple cavitating lung nodules:

- Neoplasia: metastases – in particular, squamous cell, sarcoma, melanoma and colorectal tumours.
- Infection: bacterial septic emboli, TB, aspergillosis and other fungal organisms.
- Collagen vascular disease: Wegener's granulomatosis, rheumatoid nodules.
- Granulomatous disease: histiocytosis X and sarcoidosis.
- Vascular: pulmonary emboli with infarction.

Discussion

This is a systemic condition characterized by necrotizing granulomata and a necrotizing vasculitis affecting medium to small vessels. Pulmonary Wegener's granulomatosis has a variety of presentations, which include:

- Widespread nodules that typically cavitate, have varying sizes (up to several centimetres) and show no zonal predilection. Figure **5b** is a single axial CT image showing left lower lobe pulmonary nodules that are relatively thick walled and some of which are demonstrating cavitation. A coronal reformat of the same patient is also shown (**5c**).
- Patchy alveolar infiltrates/consolidation/'ground glass' opacity.
- Lymphadenopathy is a rare feature.
- Pleural effusions can be seen.

Upper respiratory tract involvement is always seen in Wegener's and features include destruction of nasal cartilage and bone, nasal mucosal ulceration, paranasal sinus mucous membrane thickening, tracheal inflammation and sclerosis resulting in stridor.

Other organ features include: glomerulonephritis, migratory polyarthropathy and skin nodules.

Practical tips

- There is a long differential for cavitating lung nodules so look for clues on the film to point towards an underlying diagnosis and also be guided by the history. Check the bones for evidence of rheumatoid arthritis and primary/secondary bone malignant lesions.
- A history of haemoptysis and renal impairment with pulmonary abnormalities on the chest radiograph brings to mind the diagnoses of Wegener's granulomatosis and Goodpasture's syndrome. Renal failure causing fluid overload may also result in pulmonary oedema that may be blood tinged.

Further management

Initial management should be referral to a respiratory physician to exclude malignant/infective causes for cavitating nodules.

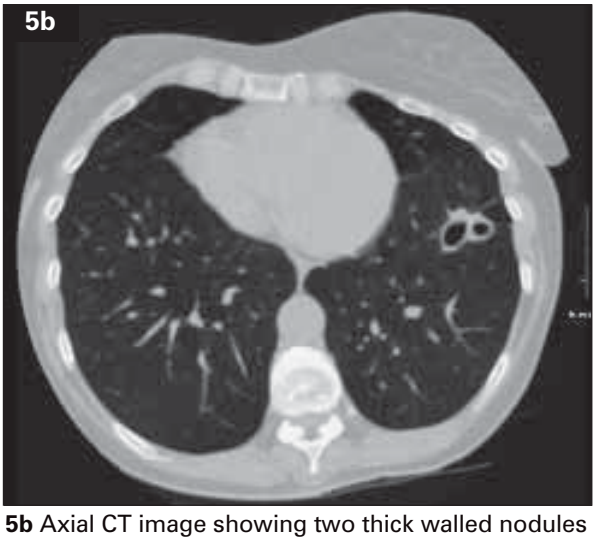

5b Axial CT image showing two thick walled nodules in the left lower lobe consistent with but not specific for Wegener's granulomatosis.

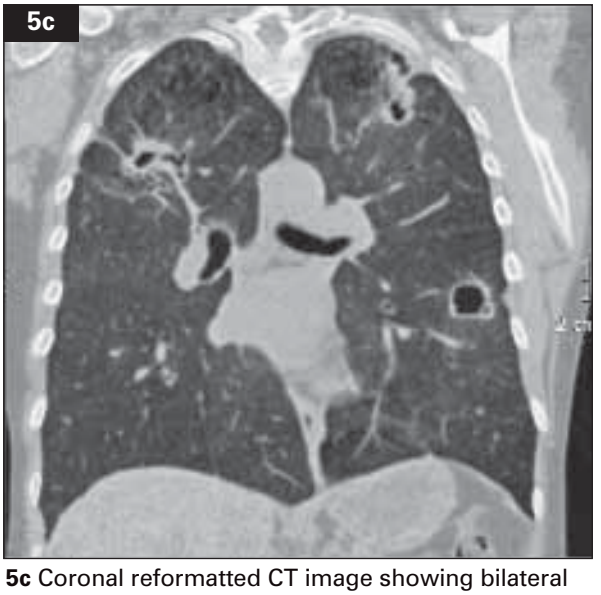

5c Coronal reformatted CT image showing bilateral cavitating nodules.

CASE 6

History

A 45-year-old female presented with progressive dyspnoea and an inflammatory arthropathy.

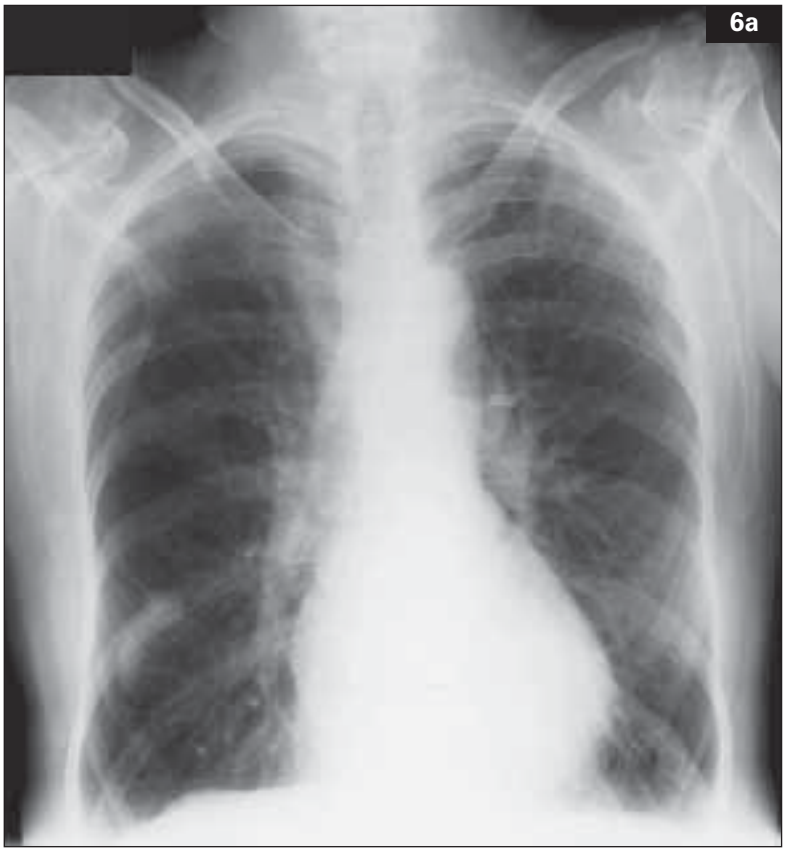

CASE 7

History

A 70-year-old factory worker presented with progressive dyspnoea.

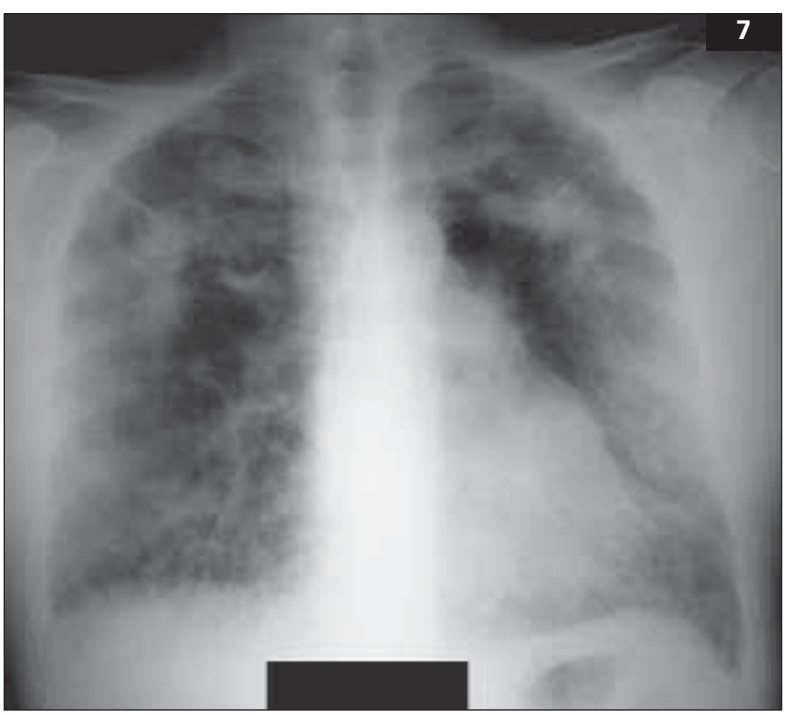

ANSWER 6

Observations (6a)

This frontal chest radiograph demonstrates a well defined pulmonary nodule in the right lower zone. This appears to be a solitary lesion. Arthropathy is noted at the left shoulder joint with associated erosion of the lateral end of the clavicle – this suggests background rheumatoid arthritis. The nodule is therefore likely to be a rheumatoid pulmonary nodule, though other pathology such as a malignant nodule cannot be excluded and follow-up is therefore required. There is no evidence of pulmonary fibrosis.

Diagnosis

Rheumatoid lung.

Differential diagnosis

For lateral end of clavicle erosion:

- Arthropathies – rheumatoid arthritis, gout, scleroderma.
- Hyperparathyroidism.
- Post-traumatic osteolysis (**6b**).
- Infection – osteomyelitis.
- Neoplastic conditions – myeloma, metastases.
- Hereditary disorders – cleidocranial dysostosis, pyknodysostosis, Holt–Oram syndrome.

Discussion

Rheumatoid lung manifestations can be seen in up to 50% of RA patients. The lung changes are more commonly found in men. CXR features of RA include:

- Interstitial fibrosis that predominantly affects the lower zones.
- Rheumatoid lung nodules – these are usually multiple, and commonly located in the lung periphery or pleurally based. They often cavitate but don't calcify.
- Pleural effusion – usually this is a unilateral exudate. More common in men.

Caplan's syndrome is a condition characterized by pneumoconiosis and RA in coal workers.

Practical tips

- Look for associated bone abnormalities if rheumatoid is suspected, e.g. resorption of the lateral ends of clavicles, erosion of the acromioclavicular, sternoclavicular and shoulder joints.
- Look for effects of drugs used to treat rheumatoid, e.g. steroid use resulting in avascular necrosis (AVN) of the humeral head or vertebral collapse.

Further management

Follow-up of single pulmonary nodules is advised to ensure that the nodule is not a developing primary bronchogenic carcinoma. Fleischner Society guidelines (*Table 1*) suggest dividing patients into high-risk (smokers and other risk factors) and low-risk categories and then organizing subsequent follow-up depending on the size of the nodule.

Further reading

MacMahon H, Austin J, Gamsu G (2005). Guidelines for management of small pulmonary nodules detected on CT scans: a statement from the Fleischner Society. *Radiology* **237:** 395–400.

6b Radiograph demonstrates erosion of the lateral edge of the right clavicle following an injury 2 years previously.

Table 1 *Follow-up guidelines for pulmonary nodules*

Nodule size (mm)	Low risk	High risk
<4	No follow-up	CT at 12 months, nil further if unchanged
4–6	CT at 12 months, nil further if unchanged	CT at 6–12 months, then 18–24 months if unchanged
6–8	CT at 6–12 months, then 18–24 months if unchanged	CT at 6 months, then 9–12 months and then 24 months if unchanged
>8	CT at 3, 9 and 24 months +/– PET CT and biopsy	CT at 3, 9 and 24 months +/– PET CT and biopsy

ANSWER 7

Observations (7)

There is widespread abnormal interstitial opacity throughout both lungs with no zonal predominance. This is predominantly of tiny nodules with some reticulation. Poorly defined heart border and hemidiaphragms indicate subpleural involvement. There are large, poorly defined conglomerate masses in both upper zones with surrounding fibrotic changes. These findings are in keeping with progressive massive fibrosis in a patient with underlying pneumoconiosis.

Diagnosis

Progressive massive fibrosis (PMF).

Differential diagnosis

For mass lesion with background pneumoconiosis:

- PMF.
- Bronchogenic carcinoma (increased incidence of adenocarcinoma in scarred lung).
- Granuloma (TB, histoplasmosis).
- Caplan's syndrome (rheumatoid nodules in those with coexisting rheumatoid).
- Any other parenchymal lesion can incidentally co-occur.

Discussion

Pneumoconiosis is a parenchymal lung reaction to chronic inorganic dust exposure. Some typical appearances on chest radiography are:

- Small nodules – silicosis, siderosis, coal worker's pneumoconiosis (CWP).
- Reticulations – asbestosis.
- Reticulonodular opacities – carbon/petroleum products.
- Interstitial pneumonia – cobalt, titanium, nickel, chromium exposure.

Progressive massive fibrosis arises as a consequence of pneumoconiosis and can develop and progress even after dust exposure has ceased. Radiologically, presentation is with large opacities in the mid/upper zones since they usually involve the posterior segment of the upper lobe and superior segment of the lower lobes. Lesions are initially seen in the lung peripheries and extend towards the hila over time. Cavitation and calcification can occur. Cavitation can then lead to secondary infection with *Aspergillus*.

Practical tips

When mass lesions appear in patients with background pneumoconiosis, remember that this may be PMF but that they are also at increased risk of adenocarcinoma.

Further management

CT chest is usually required for further characterization and it is often difficult to definitively differentiate this from bronchogenic carcinoma. In these cases, review within a lung cancer multidisciplinary team setting is required with a view to percutaneous lung biopsy.

CASE 8

History

A 30-year-old male presented with haemoptysis and shoulder pain.

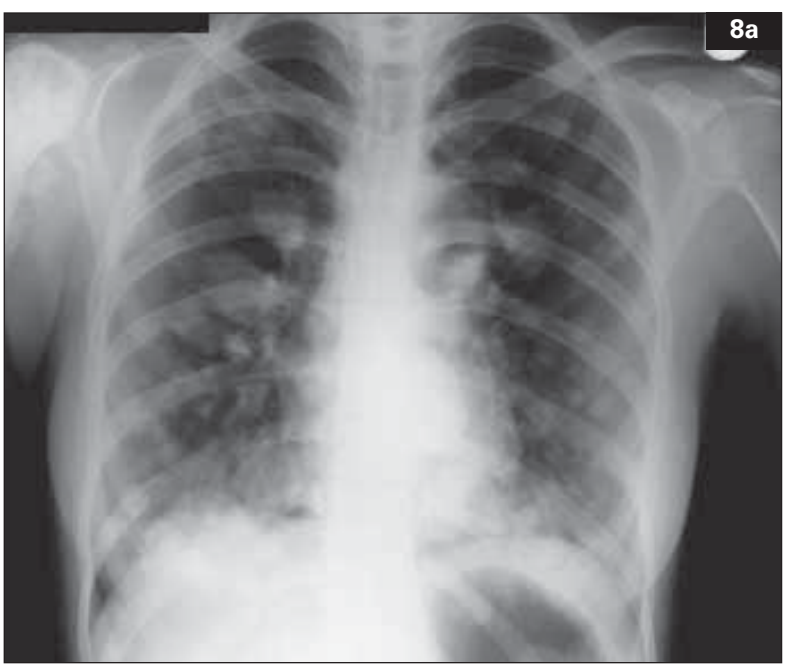

ANSWER 8

Observations (8a)

There are several well defined soft tissue density nodules throughout both lungs with no zonal predominance. The right humerus is seen on the edge of the film and is abnormal in appearance with mottled sclerotic density and apparent periosteal reaction. Further imaging of it is required but the suspicion from this film must be of a sarcoma of the right humerus with associated pulmonary metastases.

Diagnosis

Lung metastases with underlying osteosarcoma.

Differential diagnosis

For multiple lung nodules:

- Neoplastic:
  - Malignant – metastases.
  - Benign – arteriovenous malformation (AVM).
- Infectious:
  - Granulomas – TB, histoplasmosis, coccidioidomycosis, cryptococcus.
  - Abscesses.
  - Septic emboli.
- Noninfectious:
  - Wegener's granulomatosis.
  - Rheumatoid arthritis (RA).
- Infarcts.
- Sarcoid.
- Amyloid.

Discussion

An AP view of the proximal right humerus from this patient is shown (**8b**). It demonstrates a pathological fracture of the right upper diaphysis with a poorly defined underlying lesion involving the metadiaphysis. This has a wide zone of transition with lytic mottled areas and sclerosis. Periosteal reaction is evident and appearances most likely indicate an osteosarcoma.

Metastases to the lung are common and are seen in up to 30% of all patients with malignancy. Common primary tumours are breast, prostate, colon, renal cell carcinoma, melanoma and osteogenic sarcoma. Some clue to the underlying primary can be suspected from the appearances of the metastatic lesion. Squamous cell carcinomas, colon, melanoma, osteosarcoma and cervix metastases are more likely to cavitate. Breast, thyroid, osteosarcoma, testes and ovarian metastases are more likely to calcify. Metastases are commonly multiple and are found in a subpleural location.

Practical tips

- Carefully check that the nodules are truly pulmonary. If no nodules project outside a region of lung covered by ribs, could they be bony? Do nodules extend into the subcutaneous tissues? Figure **8c** shows multiple skin nodules in neurofibromatosis masquerading as pulmonary nodules!

8b AP view of the proximal right humerus from this patient showing a poorly defined lesion in the metadiaphysis of the right humerus with a wide zone of transition, lytic and sclerotic areas. Periosteal reaction is also seen. This is likely to be an osteosarcoma.

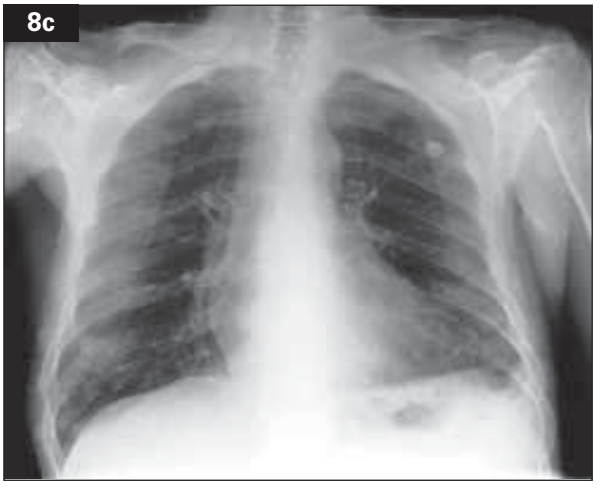

8c Chest radiograph of a patient with neurofibromatosis type 1 with multiple skin nodules.

- Look carefully at the film for a primary malignancy (as in this case) and also metastases elsewhere, such as bone deposits or calcified liver deposits under the right hemidiaphragm.
- Look for cavitation and/or calcification in the nodules to point towards underlying primary/diagnosis.

Further management

- CT chest can identify further nodules and can help to characterize them, i.e. looking for central necrosis, fat, calcification, cavitation.
- Where a primary malignancy cannot be identified then percutaneous biopsy or a surgical video-assisted thorascopic surgery (VATS) procedure can obtain tissue from a nodule for histological characterization.

Further reading

Winer-Muram HT (2006). The solitary pulmonary nodule. *Radiology* **239:** 34–49.

CASE 9

History

A 45-year-old male smoker presented with a cough.

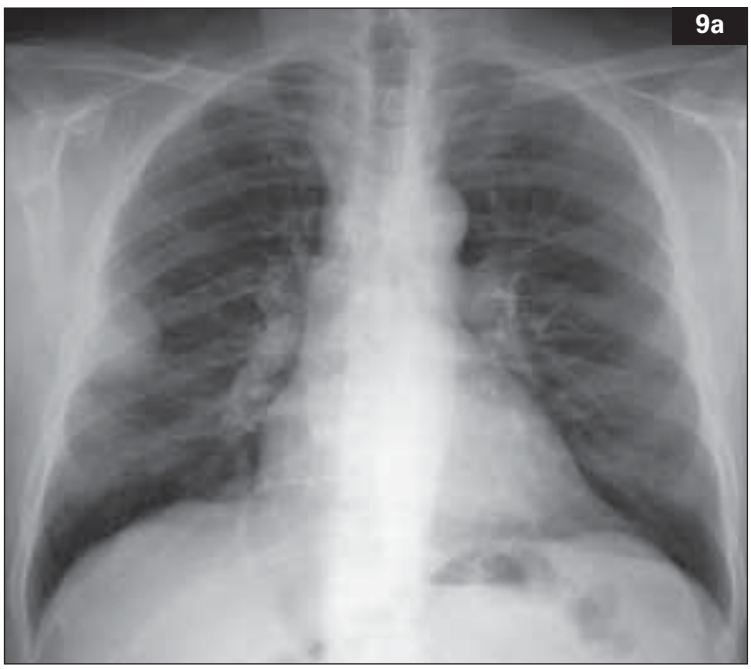
9a

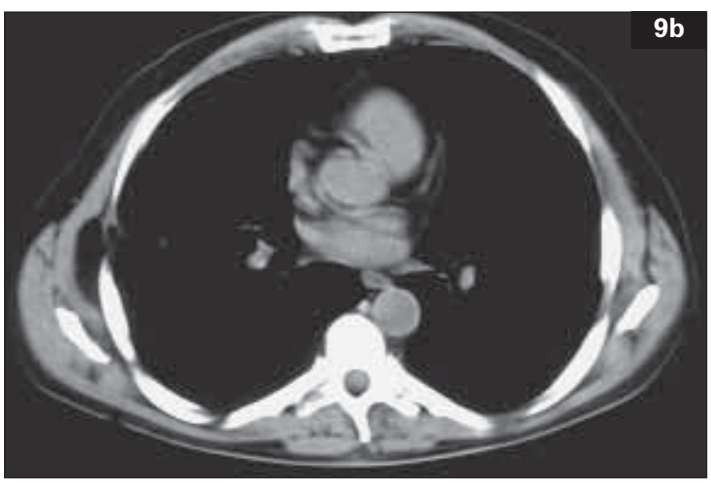
9b

ANSWER 9

Observations (9a, 9b)

PA chest radiograph (**9a**) shows a well defined lesion in the periphery of the right lung forming an obtuse angle with the chest wall. This is consistent with a pleurally based lesion. The single axial image from a CT thorax examination (**9b**) shows a lucent lesion of fat density that extends through the chest wall to a subpleural location.

Diagnosis

Chest wall lipoma.

Differential diagnosis

For pleural lesions:

- Metastasis – lung and breast are the most common primaries, with other adenocarcinomas such as ovary, uterus, pancreas.
- Pleural plaques.
- Loculated pleural effusion.
- Haematoma.
- Lipoma.
- Neurofibroma/schwannoma.
- Rib lesions such as tumour or even healing fracture can be hard to differentiate from pleural lesions. (Figure **9c** is an axial CT image showing a rib-based lesion causing complete destruction of the posterior right 8th rib. The patient had myeloma and appearances are those of a plasmacytoma.)

Discussion

Imaging features on a plain radiograph can usually be used with a good degree of confidence to differentiate pleural lesions from a lung parenchymal lesion.

Important differentiating features that point to a pleural location include:

- Obtuse angle with the chest wall.
- Smooth tapering edges.
- Peripheral location.

Practical tips

- When a pleural soft tissue mass is identified, carefully check the film for supporting evidence of background malignancy.
- An underlying rib fracture points to a subpleural haematoma.
- US can be helpful with the differentiation by determining whether the pleural lesion is fluid or solid.

Further management

No further treatment required for this benign lesion.

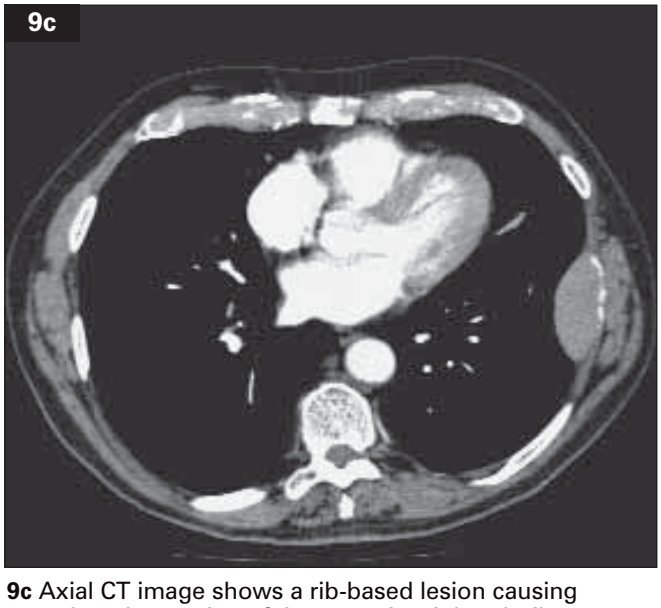

9c Axial CT image shows a rib-based lesion causing complete destruction of the posterior right 8th rib.

CASE 10

History

A 76-year-old male presented with chest pain.

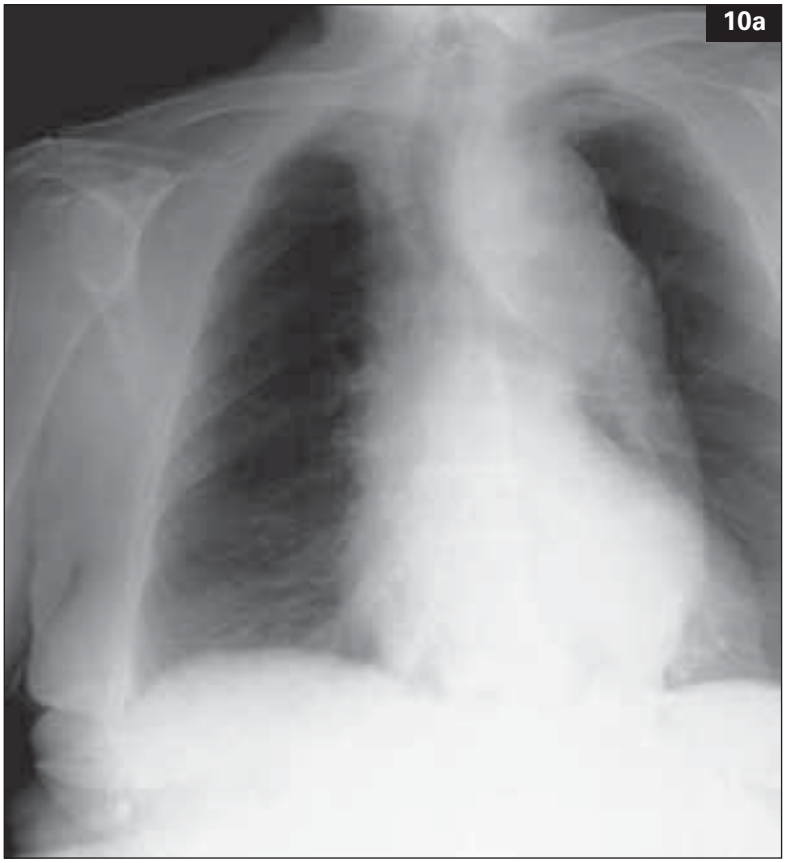

CASE 11

History

A 67-year-old male presented with shortness of breath.

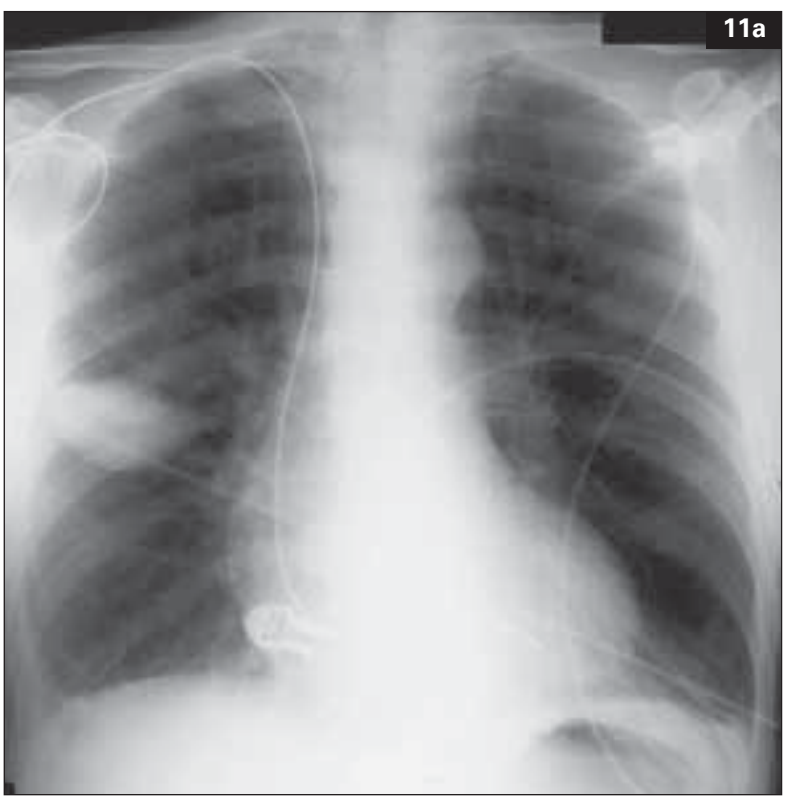

ANSWER 10

Observations (10a)

This AP chest radiograph demonstrates a large mediastinal mass on the left. The arch of the aorta and proximal descending aorta are not seen separate from this mass, which indicates that it arises from the posterior mediastinum. There is curvilinear calcification in the lateral aspect of this mass, which would suggest that the lesion is in fact a dilated aneurysmal thoracic aorta. Comparison with old films would be useful to assess any change.

Diagnosis

Thoracic aortic aneurysm.

Differential diagnosis

Of posterior mediastinal mass:
- Thoracic aortic aneurysm.
- Dilated oesophagus.
- Hernia – hiatus, Bochdalek's.
- Neurogenic tumour – neurofibroma, schwannoma, ganglioneuroma.
- Spinal abscess.
- Extramedullary haematopoiesis.

Of anterior mediastinal mass:
- Thymoma.
- Teratoma.
- Thyroid enlargement with retrosternal extension.
- Lymphoma.

Of middle mediastinal mass:
- Lymph nodes.
- Bronchogenic/duplication cyst.
- Ascending aortic aneurysm.
- Carcinoma of bronchus/trachea.

Discussion

An axial CT image (**10b**) of the chest with IV contrast shows the descending aortic aneurysm. Typical radiological appearances are of a mediastinal mass – the wide tortuous aorta with peripheral curvilinear calcification. Normal CT measurements for the thoracic aorta are <3.5 cm diameter for the ascending aorta and <2.5 cm for the thoracic descending aorta. Surgical repair is considered over 6 cm. In the acute situation, where no old films are available, differentiation from an acute aortic dissection may be necessary. In acute aortic dissection there can be widening of the mediastinum, an irregular fuzzy appearance to the aortic outline and displacement of calcification with additional soft tissue identified lateral to calcification (due to false channel formation).

Characterizing the position of mediastinal masses is useful on plain radiography in order to narrow the differential diagnosis:
- Posterior mediastinum is the space between the posterior aspect of the heart and the thoracic spine, and contains descending aorta, oesophagus, azygous veins and thoracic duct.
- Middle mediastinal space contains heart and great vessels.
- Anterior mediastinal space is from the anterior aspect of the heart to the sternum, and contains thymus and lymph nodes.

Knowing the contents of each space and applying the silhouette sign allows for better identification of what a mediastinal mass may be. For example, in Figure **10c** there is a large, well defined, round mediastinal mass related to the left heart border. The left heart border can be clearly seen, therefore the mass cannot be within the middle mediastinum. Although slightly difficult to assess the region behind the heart, no clear separation can be made between the rounded lesion and the descending aorta, suggesting that the lesion is a posterior mediastinal mass. This is confirmed by the lateral film (**10d**) in the same patient and the lesion was proved to be a neurofibroma.

Practical tips

Lateral films can be very useful in better localizing mediastinal masses.

Further management

If there is clinical concern then CT is usually the next investigation of choice.

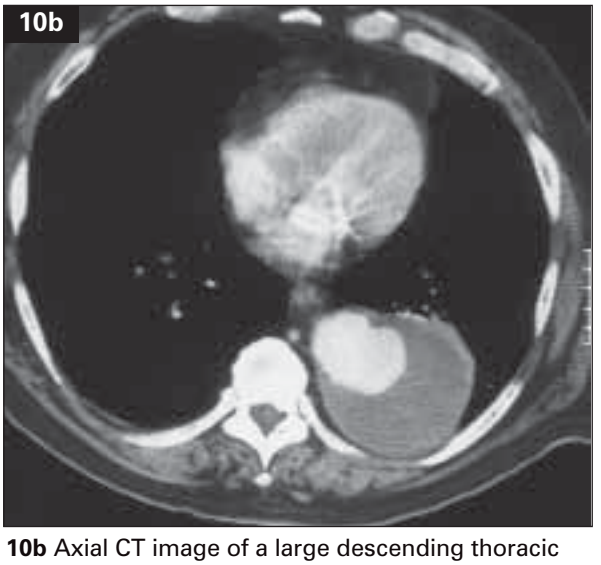

10b Axial CT image of a large descending thoracic aortic aneurysm with marked thrombus.

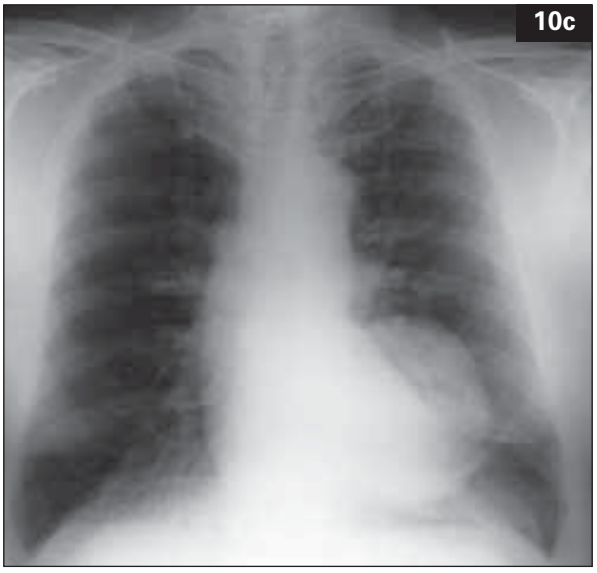

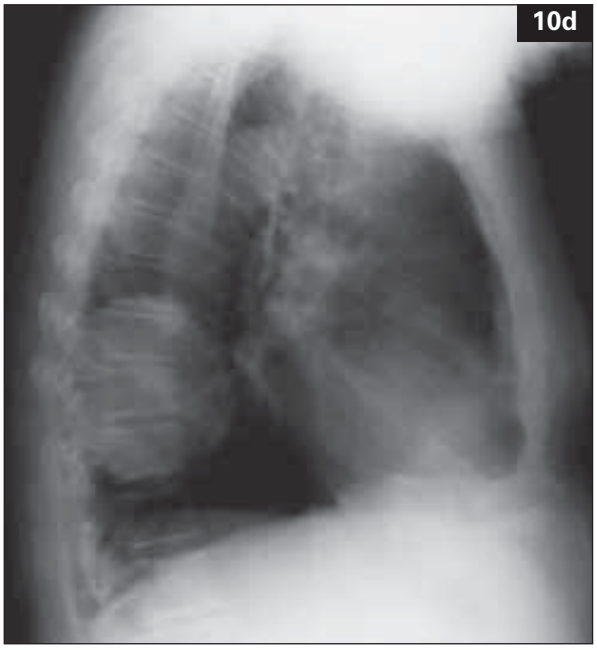

10c, 10d AP and lateral chest radiographs show a posterior mediastinal mass.

ANSWER 11

Observations (11a)

This PA chest radiograph shows a very well defined 5 cm soft tissue density lesion in the right mid zone, in the region of the horizontal fissure. The heart is enlarged with cardiothoracic ratio of 16:26. There is upper zone venous congestion and a slight increase in interstitial opacity. These appearances are in keeping with left heart failure and the right sided opacity could therefore indicate localized pleural fluid in the oblique fissure. Comparison with any recent films or, alternatively, a follow-up film after treatment should confirm resolution of the opacity.

Diagnosis

Pleural pseudotumour.

Differential diagnosis

For solitary lung nodule/mass:

- Neoplastic:
  - Malignant – primary bronchogenic carcinoma, solitary metastasis.
  - Benign – hamartoma, adenoma, arteriovenous malformation (AVM).
- Infectious:
  - Granuloma – TB, histoplasmosis, coccidioidomycosis, cryptococcus.
  - Abscess.
  - Septic embolus.
- Non-infectious:
  - Wegener's granulomatosis.
  - Rheumatoid arthritis (RA).
  - Infarct.
  - Sarcoid.
  - Amyloid.
- Congenital:
  - Bronchogenic cyst.
  - Sequestration.
- Extrapulmonary:
  - Pleural mass/fluid.
  - Rib fracture/lesion.
  - Subcutaneous lesion.
  - External artefact.

Discussion

This is focal accumulation of fluid in the interlobar fissure and is identified on the chest radiograph as having very well defined inferior borders. There are often other features of pleural fluid elsewhere, or features to indicate background pathology such as heart failure that has led to pleural fluid accumulation. The main importance of such a condition is that there is potential to misinterpret it as a focal pulmonary nodule/mass.

(*cont.*)

Practical tips

- Important features in differentiating solitary lesions include:
  - Growth rate – lesions that don't change in size over a period of 2 years can be considered benign. Tumour doubling times (time taken for volume of nodule to increase twofold) have been reported between 1 and 18 months.
  - Margins – irregularity, lobulation and spiculation of the lesion's edge are a good indicator of malignancy. However, 30% of lesions with smooth margins are not benign – usually representing metastases.
  - Presence of fat – this is usually a sure sign of benignity and suggests the diagnosis of a hamartoma. Very occasionally renal cell carcinoma and liposarcoma metastases can also contain fat.
  - Calcification – this is seen in both benign and malignant conditions. Benign lesions usually have calcification with a central nidus, laminated or popcorn appearance. Calcification in malignant lesions usually appears stippled, amorphous or diffuse. Stippled calcification is seen in mucin secreting tumour metastases, e.g. colon, ovary.
  - Cavitation – again this is seen in both benign and malignant lesions. Irregular thick walled cavities are more likely to be malignant than thin, smooth walled ones.

- When an apparent pulmonary opacity has an unusual shape or density, always stop and ask 'could it be in the pleura, chest wall, soft tissue or even external to the patient?' Figure **11b**, for example, shows a very sharply defined calcific density opacity in the right lower zone. It is difficult to imagine what pulmonary pathology this might represent and it is actually a calcified breast fibroadenoma.

Further management

Lateral CXR can be helpful in these cases and if there is still concern then CT chest will usually resolve the issue. (See Case 6, *Table 1* for further management of single pulmonary nodule.)

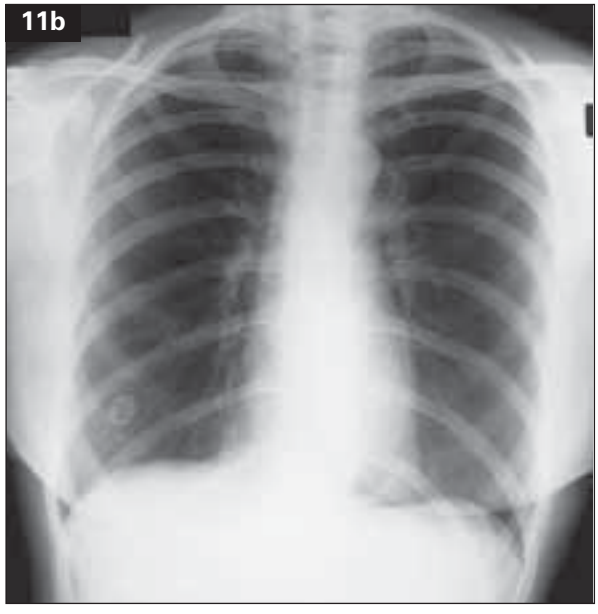

11b Chest radiograph shows a very well defined calcific density in the right lower zone, which actually represents a calcified breast fibroadenoma.

CASE 12

History

A 69-year-old male smoker with ischaemic heart disease, presented with increasing dyspnoea over the last 2 months.

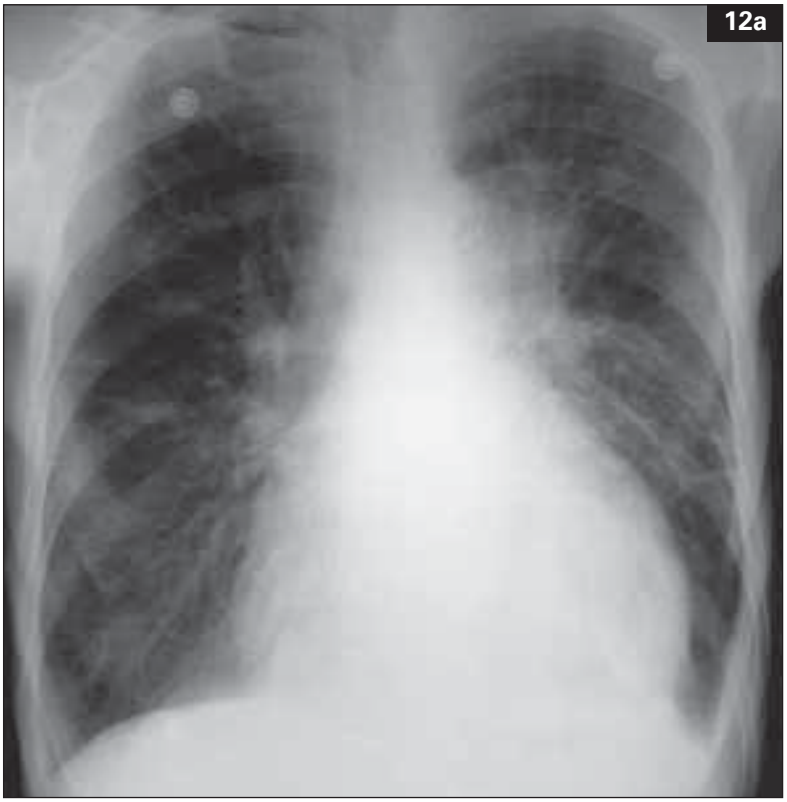

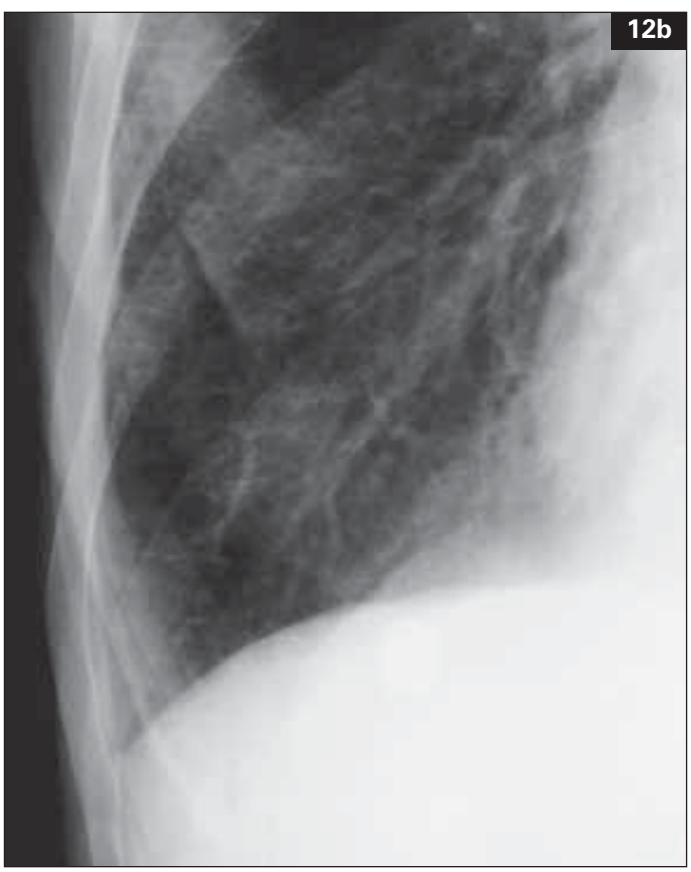

ANSWER 12

Observations (12a, 12b)

The heart looks enlarged but as this is an AP radiograph, it is not possible to be sure. There is a diffuse, bilateral increase in reticular interstitial opacity with Kerley B lines in the right lower zone best seen on the close-up (**12b**). The left hilum is enlarged, and there is a pulmonary nodule in the left upper zone measuring approximately 1.5 cm. A tiny left pleural reaction is also noted.

The most likely explanation is that the patient has a left upper lobe tumour with left hilar adenopathy and lymphangitis carcinomatosa. However, given the history of heart disease and the rather subjective cardiomegaly, it is possible that he could have lung cancer and coexisting left heart failure. A repeat film after treatment for heart failure might help clarify, but he is likely to need staging of the suspected tumour with CT anyway, and this may answer the question.

Diagnosis

Left upper lobe tumour with lymphangitis carcinomatosa.

Differential diagnosis

For tumours causing lymphangitis (anatomically from top down):

- Larynx.
- Thyroid.
- Breast.
- Stomach.
- Pancreas.
- Colon.
- Cervix.

For septal (Kerley B) lines:

- Pulmonary venous hypertension.
- Lymphangitis.

Many other conditions can show septal lines, though the two conditions above rank far above these. Examples include: sarcoid, any chronic fibrosing lung condition, lymphangiectasia, lymphangiomyomatosis, lymphoma and viral pneumonia.

For subpleural nodules:

- Sarcoid.
- Lymphangitis carcinomatosa.
- Silicosis.
- Lymphoma.

Discussion

Certain tumours show a propensity to invade the lung interstitium, both the connective tissue and the lymphatics. Lymphatics become distended by the tumour itself, and also because of congestion resulting from tumour obstruction. Symptoms include dyspnoea and cough.

Plain film signs are of increased reticular/reticulo-nodular interstitial markings, Kerley A and Kerley B lines. CT shows irregular thickening of the interlobular septae, along the central bronchovascular bundles and subpleural thickening. In addition, there are small peripheral subpleural nodules. Heart failure produces similar appearances on plain film and CT, though the thickening is more likely to be smooth and there will not be the associated lymphadenopathy that is often present in lymphangitis. Like heart failure, lymphangitis usually produces bilateral changes.

Practical tips

- When lymphangitis is diagnosed, look for other signs of malignant spread on available images, i.e. lung metastases, bone deposits.
- CT imaging findings of subpleural nodules and reticulation with interlobular septal thickening are the best diagnostic features. However, if it remains impossible to differentiate interlobular septal thickening of heart failure from lymphangitis on CT scanning, repeat imaging (chest radiograph or perhaps follow-up CT) after treatment for heart failure may resolve the issue.

Further management

Oncological assessment is necessary. If deemed suitable for chemotherapy, a search for the primary tumour is appropriate if not already apparent as in this case. CT scanning of the thorax, abdomen and pelvis is most commonly undertaken.

Further reading

Connolly JE, Erasmus JJ, Patz EF (1999). Thoracic manifestations of breast carcinoma: metastatic disease and complications of treatment. *Clinical Radiology* **54(8):** 487–494.

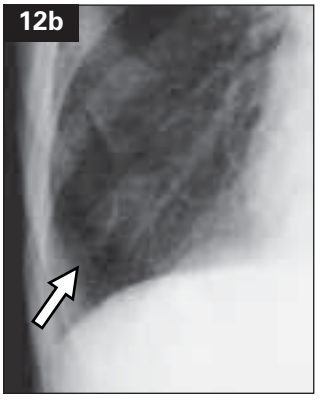

12b Kerley B septal line.

CASE 13

History

A 36-year-old female, otherwise fit and well, presented with acute dyspnoea and left sided chest pain.

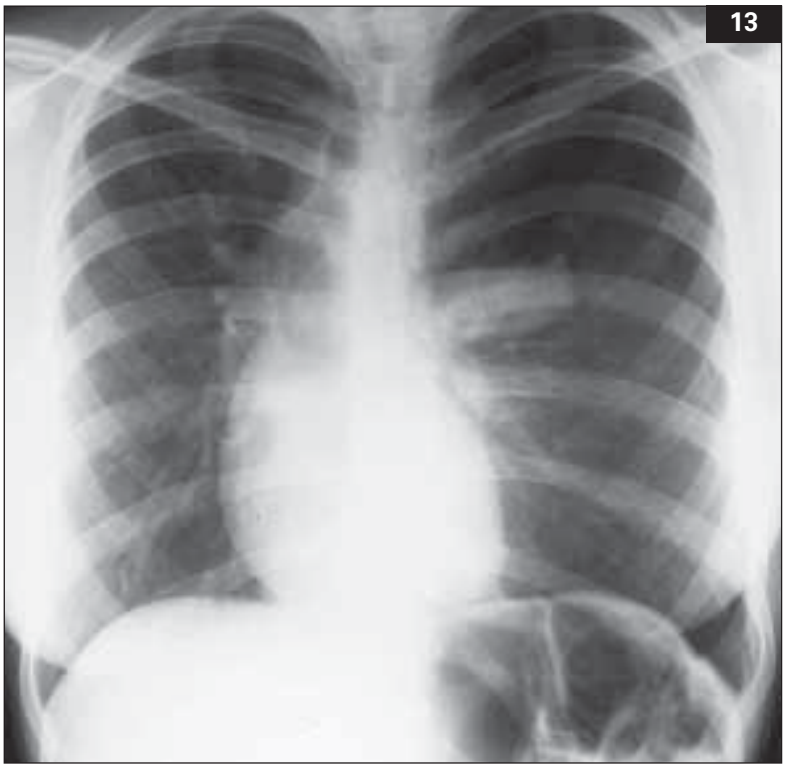

CASE 14

History

A 55-year-old man presented with dysphagia.

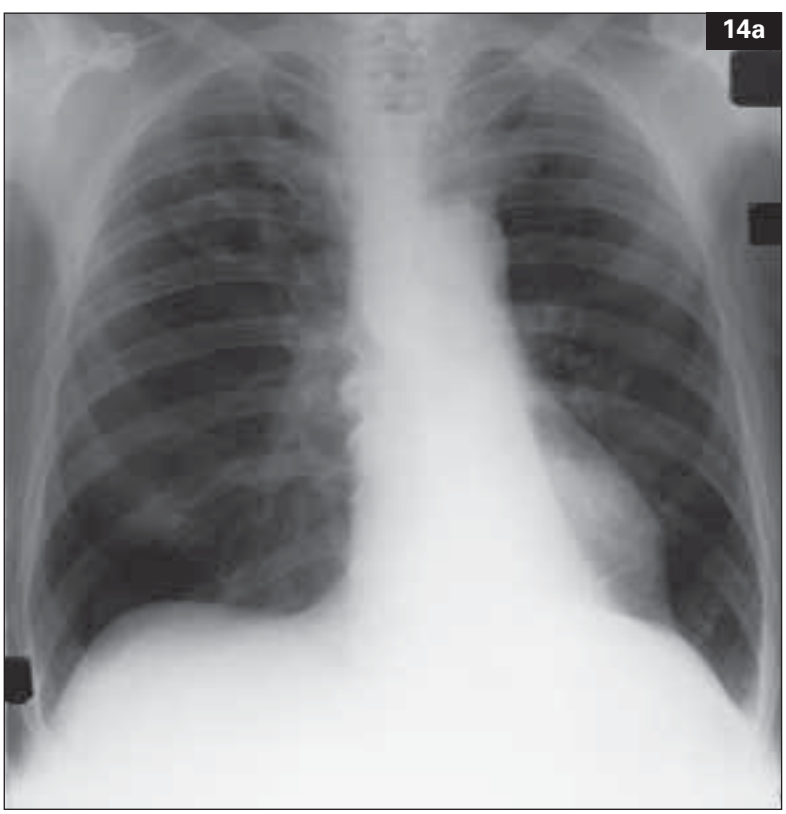

ANSWER 13

Observations (13)

There is a large, well defined, solitary, unilocular thin walled cyst in the medial aspect of the left middle zone. This contains an air-fluid level. A moderate sized left sided pneumothorax is evident with signs of mediastinal and tracheal shift to the right – suggesting that this is a tension pneumothorax. Immediate treatment of this tension pneumothorax is required.

The air-containing mass has presumably ruptured and led to a spontaneous pneumothorax. The fact that this patient is young and otherwise in good health makes most of the causes of large cavitating/cystic masses unlikely. After initial treatment, a search for previous films should be made to see if this is a longstanding benign lesion. Otherwise, further investigation, perhaps with CT, will be required.

Diagnosis

Intrapulmonary bronchogenic cyst.

Differential diagnosis

For solitary cavitating lesion:

- Cavitating neoplasm – squamous cell carcinoma of the lung is the most likely lung tumour to cavitate.
- Lung abscess.
- Cavitating pneumonia.
- Infarct/haematoma.

Discussion

Bronchogenic cysts are usually located in the mediastinum (85%) but can also be intrapulmonary in location (15%). They are more commonly found in the lower lobes and usually in the medial aspect. Typical appearances are of a solitary, unilocular thin walled cyst of uniform density due to thick mucoid fluid content. They can also contain air-fluid levels. Calcification of the wall is rare. They are usually asymptomatic but can be complicated by infection and haemorrhage or can cause compression to adjacent structures, i.e. trachea/airways/oesophagus.

Practical tips

- As always, clinical history is vital in producing a sensible differential diagnosis.
- Tension pneumothorax is an emergency and should be immediately treated or the appropriate clinician should be informed. It arises when air is able to enter the pleural space on inspiration but not escape on expiration. The accumulating air produces increasing mass effect (mediastinum displaced and diaphragm depressed) that compromises ventilation of the other lung and also cardiovascular function.

Further management

Tension pneumothorax is a medical emergency requiring immediate treatment. The increasing pressure must be relieved either with an intercostal chest drain or perhaps even insertion of a cannula into the pleural space in the acute situation.

Further reading

Matzinger M, Matzinger F, Sachs H (1992). Intrapulmonary bronchogenic cyst: spontaneous pneumothorax as the presenting symptom. *American Journal of Radiology* **158:** 987–988.

ANSWER 14

Observations (14a)

This frontal chest radiograph shows a triangular opacity behind the left side of the heart. It obscures the silhouette of the left hemidiaphragm where they meet, and there is depression of the left hilum indicating volume loss. This is the 'sail sign' of left lower lobe collapse.

At least two cavitating pulmonary nodules are present in the right upper lobe and close inspection of the mediastinum reveals residual barium in the upper thoracic oesophagus, terminating abruptly in the mid mediastinum.

The findings suggest that the patient has recently undergone a barium swallow, which has demonstrated a mid-oesophageal tumour. The pulmonary lesions on the right are likely to represent cavitating metastases and the left lower lobe collapse is presumably due to tumour obstruction of the left lower lobe bronchus.

Diagnosis

Oesophageal tumour with left lower lobe collapse and cavitating pulmonary metastases.

Differential diagnosis

Of a veil-like opacity over a hemithorax:

- Left upper lobe collapse.
- Pleural effusion in the supine position.
- Rotated patient position.
- Overlying chest wall abnormality, e.g. gynaecomastia.
- Unilateral airspace opacity.
- Normal, i.e. it is actually the other side that is hypodense!

Of a completely opaque hemithorax:

- Total lung collapse.
- Pneumonectomy – looks like total collapse but there will be evidence of thoracotomy.

- Huge pleural effusion – volume expansion rather than volume loss, i.e. the mediastinum will be displaced away from the side of opacity.

Discussion

The various lobar collapses have their own characteristic appearances but evidence of volume loss is fundamental. Signs to look for include:

- Elevation or 'tenting' of the hemidiaphragm.
- Elevation or depression of the hilum – note that the left is normally higher than right.
- Mediastinal shift in the direction of the collapse.
- Elevation or depression of the horizontal fissure.
- Increased lucency or splayed vessels in the remaining hyperexpanded lobe.

In older adults, an obstructing central tumour must always be excluded. When causing upper lobe collapse, this can sometimes produce the characteristic 'S sign of Golden' (**14b**). The right upper lobe collapses into a triangular upper zone opacity, limited inferiorly by the horizontal fissure. However, the central mass produces an overall 'S' configuration with the fissure. Figures **14c** and **14d** are axial CT images in a patient with subtotal collapse of the right upper lobe with medial collapse of the lobe and significant volume loss as demonstrated by anterior movement of the fissures. A coronal CT reformatted image (**14e**) again shows subtotal collapse of the right upper lobe with volume loss.

(*cont.*)

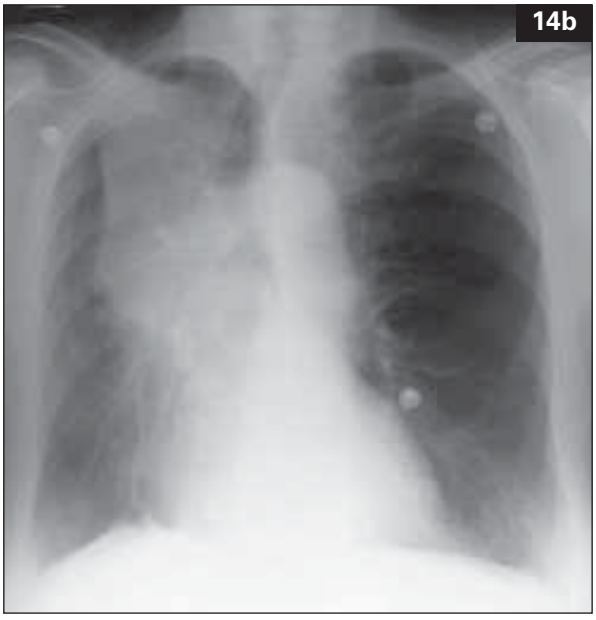

14b Right upper lobe collapse secondary to a central bronchogenic tumour produces an 'S sign of Golden'.

14c, 14d Axial CT images of the upper chest showing collapse of the right upper lobe with anterior and medial collapse. Anterior movement of horizontal and oblique fissures is demonstrated.

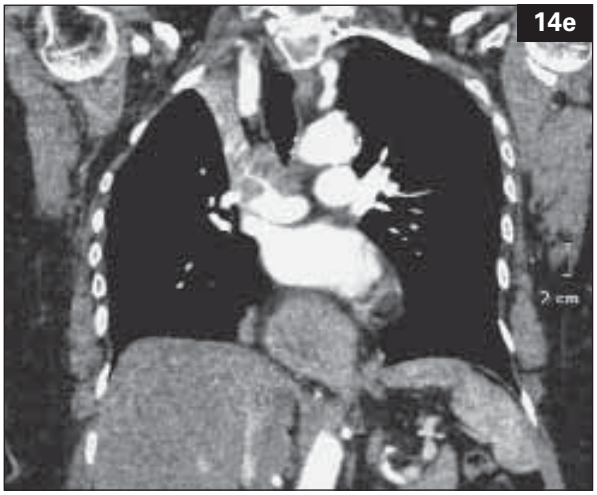

14e Coronal CT reformatted image of the chest showing the medial displacement of the collapsed upper lobe.